

Infections in immunocompromised
host (non HIV): Case based
discussion

Dr Ram Gopalakrishnan

Some general principles in approaching infection in the immune compromised host

- Take a careful history
- Classify the immune defect
- Know the timeline of infection
- Be aggressive in workup
- Molecular/rapid diagnostics essential: if not available in hospital , send out!
- May need empiric therapy pending diagnostics
- More than one infection may be present
- Watch for drug interactions between anti-microbials and other medications
- Once infection confirmed, minimize the immunosuppression where possible

Solid organ transplant timeline

- First 30 days
 - Site specific and hospital acquired infections
- 30-90 days
 - Infections related to immuno-suppression
- After 90 days
 - Community acquired infections
 - OI depending on level of immune suppression

Classify the immune defect

- Granulocytopenia
- Damaged skin/mucosae
- Impaired cellular immunity
- Impaired humoral immunity
- Splenectomy
- Ciliary motility defect

Defect

Pathogen

Granulocytopenia

Gram-positive cocci

Staphylococcus aureus

Coagulase-negative staphylococci (*epidermidis*,
haemolyticus, *hominis*)

Viridans group streptococci (*mitis*, *oralis*)

Granulicatella and *Abiotrophia* species (formerly
nutritionally variant streptococci)

Enterococci (*faecalis*, *faecium*)

Gram-negative bacilli

Escherichia coli

Pseudomonas aeruginosa

Klebsiella pneumoniae

Enterobacter and *Citrobacter* species

<p>Damaged Integument Skin-central venous catheter related</p>	<p>Coagulase-negative staphylococci (<i>epidermidis</i>, <i>haemolyticus</i>, <i>hominis</i>) <i>Staphylococcus aureus</i> <i>Stenotrophomonas maltophilia</i> <i>Pseudomonas aeruginosa</i> <i>Acinetobacter</i> species Corynebacteria <i>Candida</i> species (<i>albicans</i>, <i>parapsilosis</i>) <i>Rhizopus</i> species</p>
<p>Oral mucositis</p>	<p>Viridans group streptococci (<i>mitis</i>, <i>oralis</i>) <i>Abiotrophia</i> and <i>Granulicatella</i> species (nutritionally variant streptococci) <i>Capnocytophaga</i> species <i>Fusobacterium</i> species <i>Rothia mucilaginosa</i> <i>Candida</i> species (<i>albicans</i>, <i>tropicalis</i>, <i>glabrata</i>) Herpes simplex virus</p>
<p>Gut mucosal barrier injury</p>	<p><i>Escherichia coli</i> <i>Pseudomonas aeruginosa</i> Coagulase-negative staphylococci Enterococci (<i>faecalis</i>, <i>faecium</i>) <i>Candida</i> species</p>
<p>Neutropenic enterocolitis</p>	<p><i>Clostridium</i> species (<i>septicum</i>, <i>tertium</i>) <i>Staphylococcus aureus</i> <i>Pseudomonas aeruginosa</i></p>

Impaired humoral
immunity

Streptococcus pneumoniae
Haemophilus influenzae

Compromised organ
function

Spleen

Streptococcus pneumoniae
Haemophilus influenzae
Neisseria meningitidis

Deferoxamine for iron
overload

Rhizopus species

Impaired cellular immunity

Herpesviruses

Cytomegalovirus

Respiratory viruses

Listeria monocytogenes

Nocardia species

Mycobacterium tuberculosis

Nontuberculous mycobacteria

Pneumocystis jirovecii

Aspergillus species

Cryptococcus species

Histoplasma capsulatum

Coccidioides species

Penicillium marneffei

Toxoplasma gondii

Case

- 60 Yr/Male
- HT
- NHL with bone marrow involvement (Feb 2015)
- On chemotherapy (R- CHOP) (10th - 14th FEB)
- Episode of febrile neutropenia requiring admission (19th -25th Feb) treated with cefoperazone-sulbactam (cultures were sterile)
- Pt improved and discharged

- 2nd cycle of chemotherapy 11/03/2015
(vincristin, rituximab)
- Patient was on steroids

- Present admission (15/03/2015)
Altered sensorium since 1 day
 No other localizing signs or symptoms

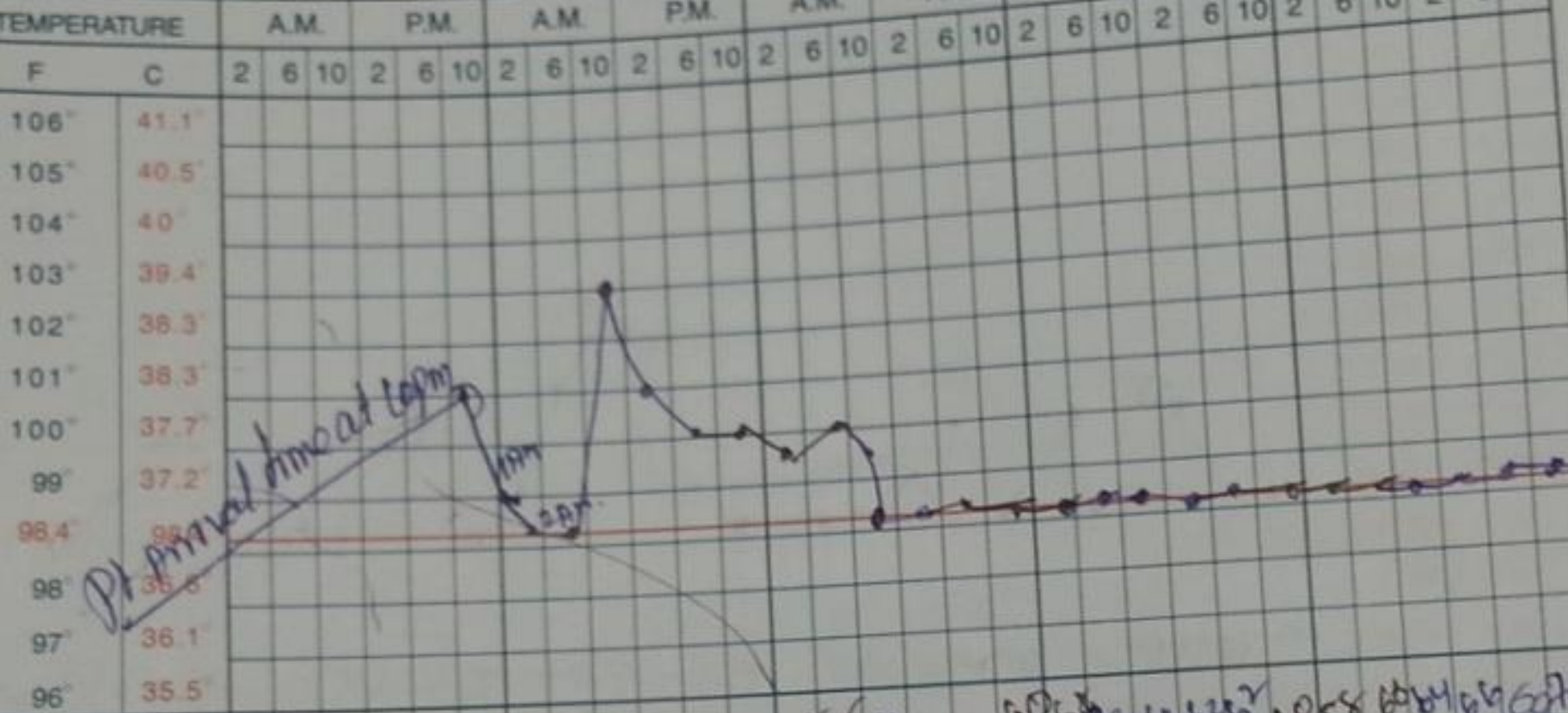- On admission temp 101 F
Hypotension requiring ionotropic support

Lab investigations

- Hb 7.5
- Tc 200
- Platelet 4000
- S. Na 122
- Chest X ray clear

- Patient was empirically started on
- Inj Meropenem, teicoplanin and fluconazole

DATE	14/3/15	15/3/15	16/3/15	17/3/15	18/3/15
HOSPITAL DAYS	(01)	(02)	3	4	5
POST OP / POST PROCEDURE					



Pt. arrived home at 6pm

PULSE RATE	116	98	132	134	120	110	104	118	93	78	80	60	60	62	64	62	60	58	60	64	64	60	
RESPIRATION	20	20	22	22	22	20	20	20	25	22	20	20	14	16	14	16	16	16	16	16	18	17	18

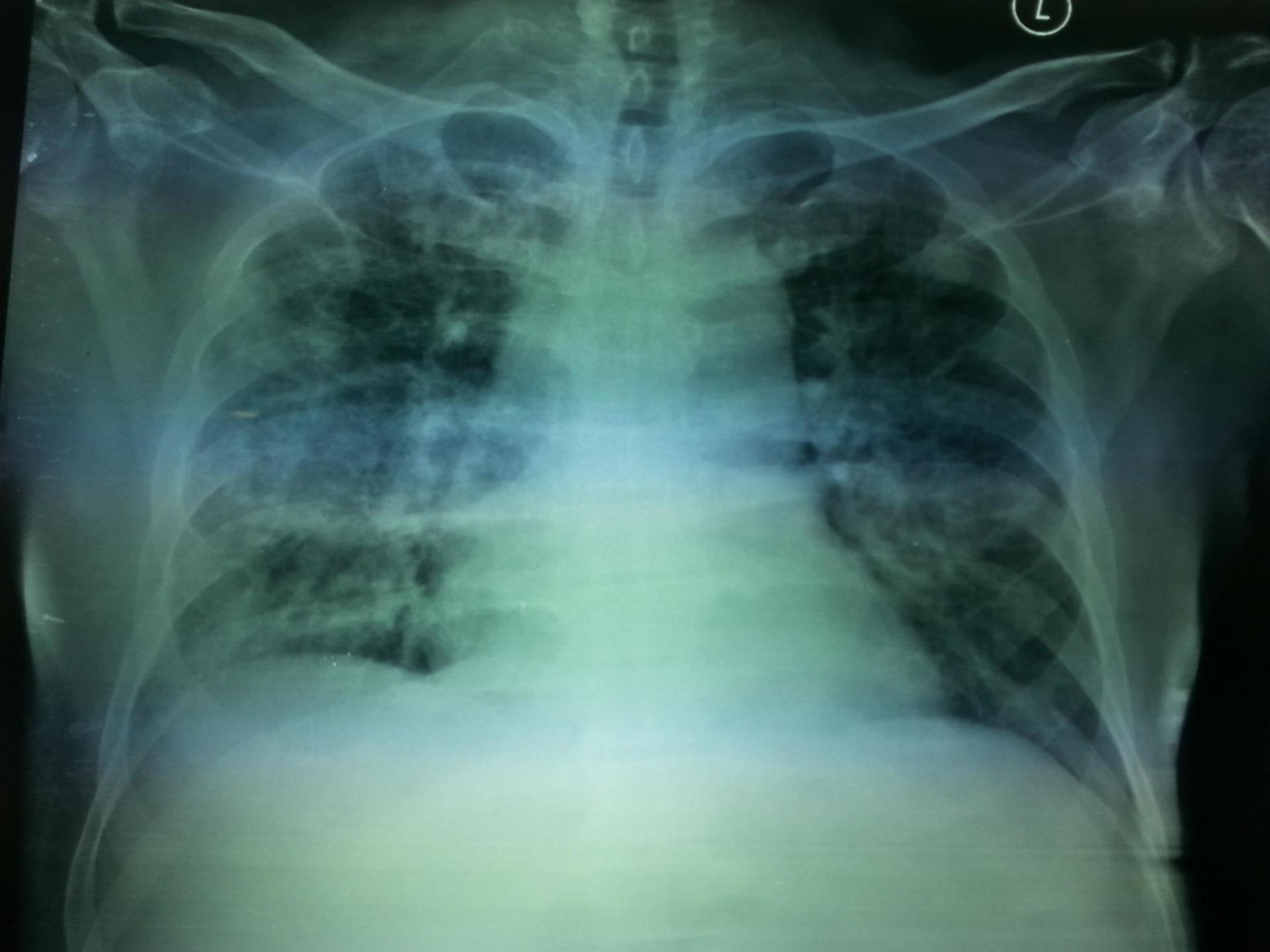PAIN SCORE	10
	9
	8
	7
	6
	5
	4
	3
	2
	1
	0

- After 5 days patient again started running high grade fever
- Cough with blood tinged expectoration
- Neutropenic (Tc 200)
- ? Clinical diagnosis
- What investigation?
- Empirical treatment?

DATE		19/3/15		20/3/15		21/3/15		22/3/15		23/3/15			
HOSPITAL DAYS		6		7		8		9		10			
POST OP POST PRODY													
TEMPERATURE		A.M. P.M.		A.M. P.M.		A.M. P.M.		A.M. P.M.		A.M. P.M.			
F	C	2	6	10	2	6	10	2	6	10	2	6	10
106	41.1°												
105	40.5°												
104	40°												
103	39.4°												
102	38.3°												
101	38.3°												
100	37.7°												
99	37.2°												
98.4	98.4°												
98	36.6°												
97	36.1°												
96	35.5°												
PULSE RATE		84 84 84 84		82 84 84 84		84 84 84 84		82 84 84 84		84 84 84 84			
RESPIRATION		20 22 20 20		20 20 20 20		20 20 20 20		20 20 20 20		20 20 20 20			



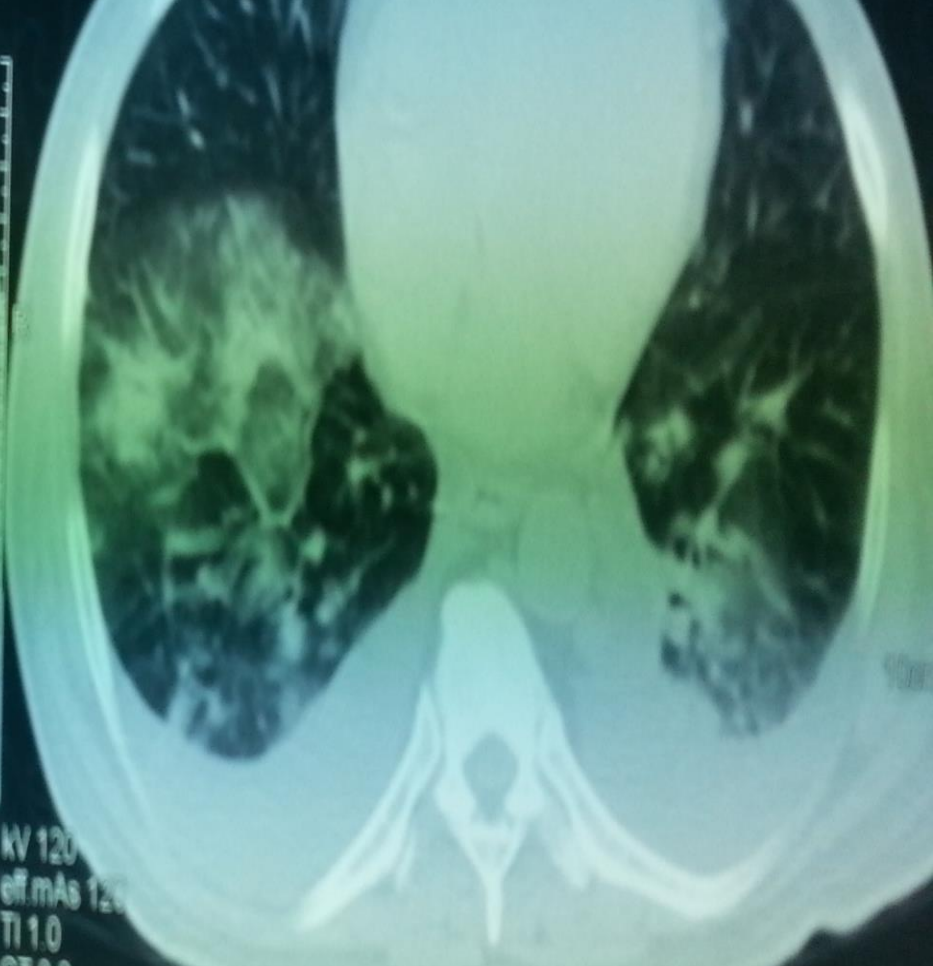
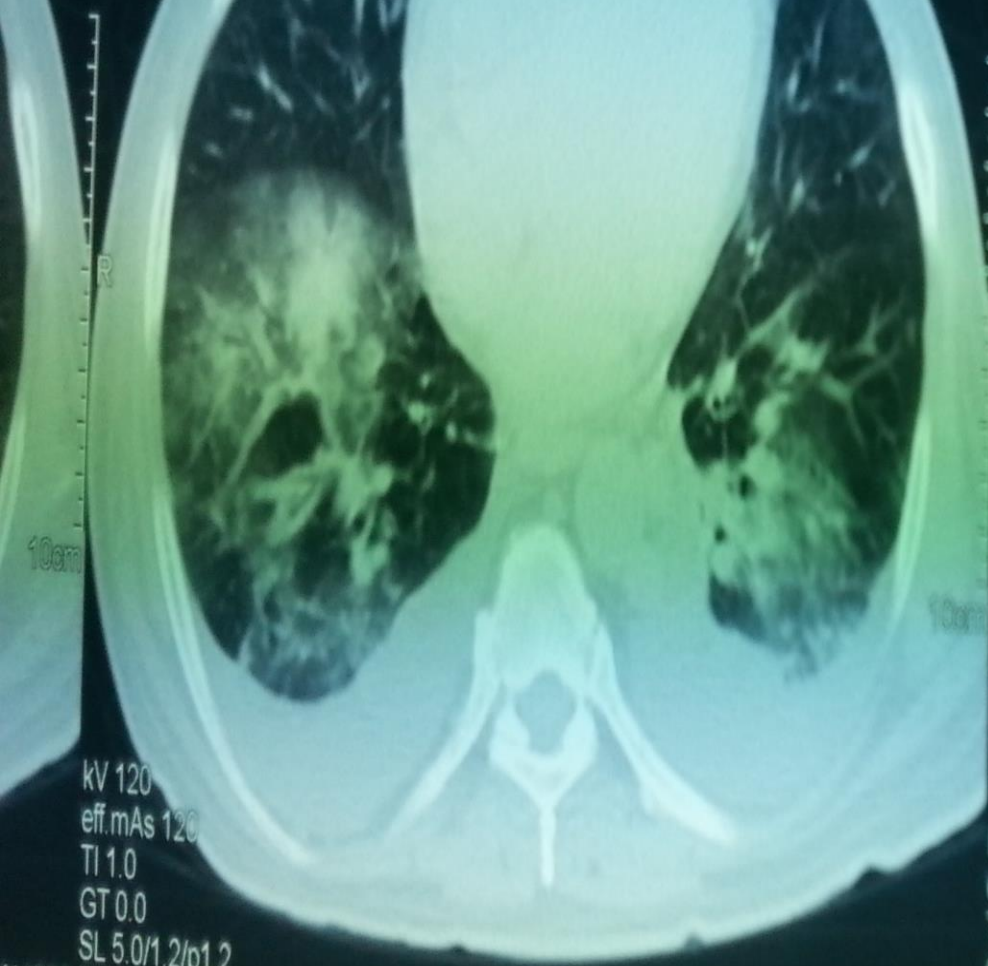
DATE		24/3/15		25/3/15		26/3/15		27/3/15					
HOSPITAL DAYS		11		12		13		14					
POST OP POST PRODY													
TEMPERATURE		A.M. P.M.		A.M. P.M.		A.M. P.M.		A.M. P.M.					
F	C	2	6	10	2	6	10	2	6	10	2	6	10
106	41.1°												
105	40.5°												
104	40°												
103	39.4°												
102	38.3°												
101	38.3°												
100	37.7°												
99	37.2°												
98.4	98.4°												
98	36.6°												
97	36.1°												
96	35.5°												
PULSE RATE		84 84 84 84		84 84 84 84		84 84 84 84		84 84 84 84					
RESPIRATION		20 20 20 20		20 20 20 20		20 20 20 20		20 20 20 20					
PAIN SCORE		10 9 8		10 9 8		10 9 8		10 9 8					



CT 2006A # 10102.315014238
H-SP-CR 24-Mar-2015
15:56:15.93
3 IMA 36
SPI 2
SP -1260.7

Sensation Open 13-Dec-1997, M, 63Y
CT 2006A # 10102.315014238
H-SP-CR 24-Mar-2015
15:56:16.07
3 IMA 37
SPI 2
SP -1265.7

Sensation Open
CT 2006
H-SP-C



kV 120
eff.mAs 120
TI 1.0
GT 0.0
SL 5.0/1.2/p1.2
W 1500 500 0/0
C -450 B70s S3C0 2

kV 120
eff.mAs 120
TI 1.0
GT 0.0
SL 5.0/1.2/p1.2
W 1500 500 0/0

Diagnosis is

- 1. CRE
- 2. Mucormycosis
- 3. Aspergillosis
- 4. TB
- 5. Nocardiosis

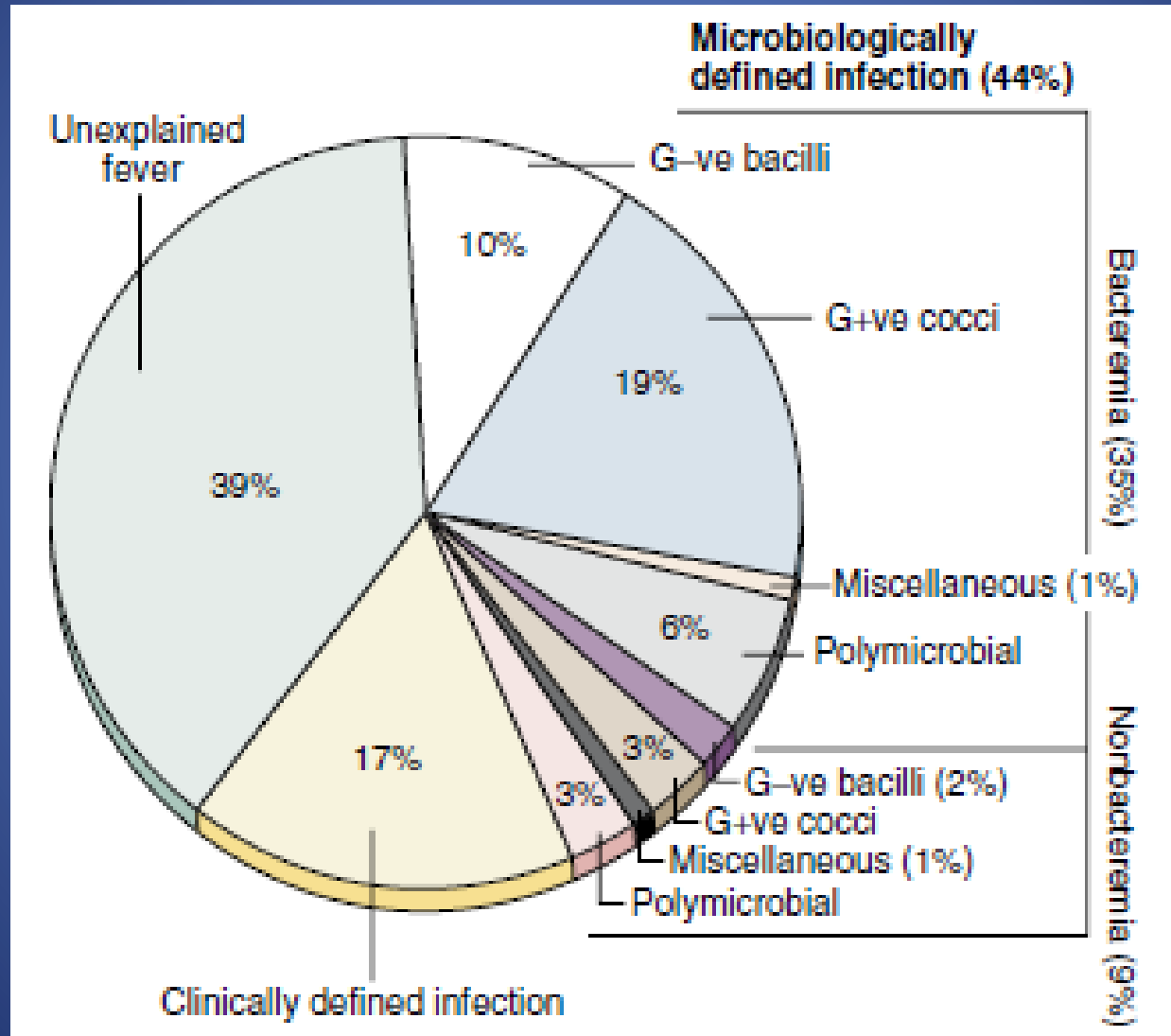
Invasive Aspergillosis

- BAL GM = 3.0
- Responded to voriconazole

Febrile neutropenia

- Fever is a single oral temperature measurement of $\geq 38.3^{\circ}\text{C}$ or a temperature of $\geq 38.0^{\circ}\text{C}$ sustained for a 1-h period
- **Neutropenia** is defined as an ANC of < 500 cells/mm³ or an ANC that is expected to decrease to < 500 cells/mm³ during the next 48 hours
- “functional neutropenia” patients are also at risk
- Febrile neutropenia: target TTA of less than 30 minutes (3.0 percent vs. 18.1 percent mortality for 30-60 mts)

Causes of febrile neutropenia



Persistent febrile neutropenia in PSCT/high risk AML/MDS: think fungus

- Empirical approach
 - Start antifungals immediately
 - Always indicated in the hemodynamically unstable patient
- Pre-emptive approach
 - Make a diagnosis with biomarkers and CT
 - Preferred approach in the stable patient

Case

25 Year male

Post renal transplant (DDRT) 2015

Chronic Graft dysfunction

2015 - Graft Pyelonephritis, Graft renal calculous, Post Mini PCNL

Feb 2017 - E.Coli Urosepsis

Immunosuppression :

Prednisolone 5 mg OD

Tacrolimus 1 mg BD

MMF 360 mg BD

Cough - 1 week, more in intensity for past 2 days - no expectoration

Fever - 2 days

No sick contacts / travel

No h/o TB or exposure

Examination :

Tachypnoeic, Tachycardic

BP - stable

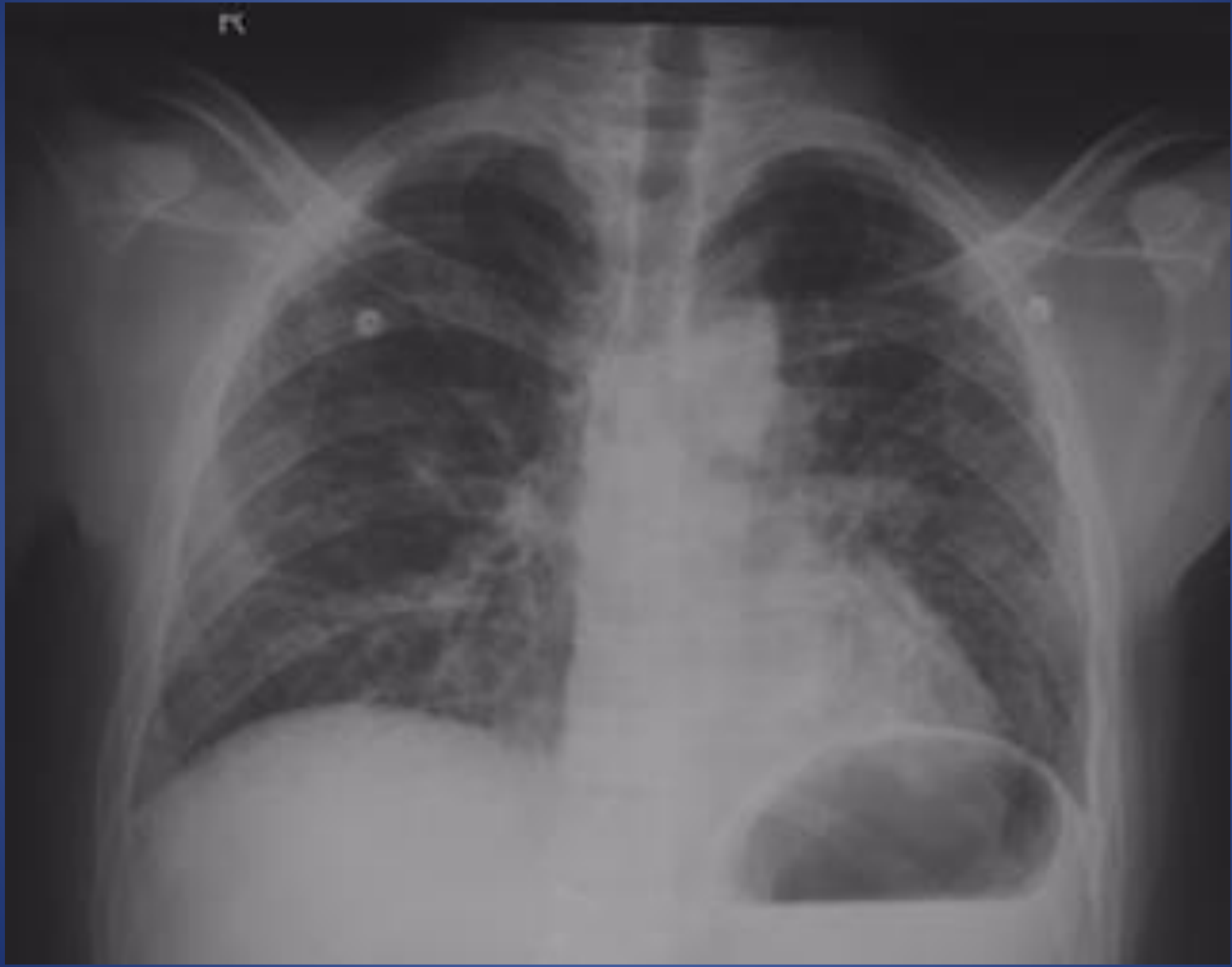6 L of O₂

b/l crackles

WBC – 7050 (80 % N)

Platelet - 2,14,000

Creat – 2.7



H1N1 - negative

Blood cultures - No growth

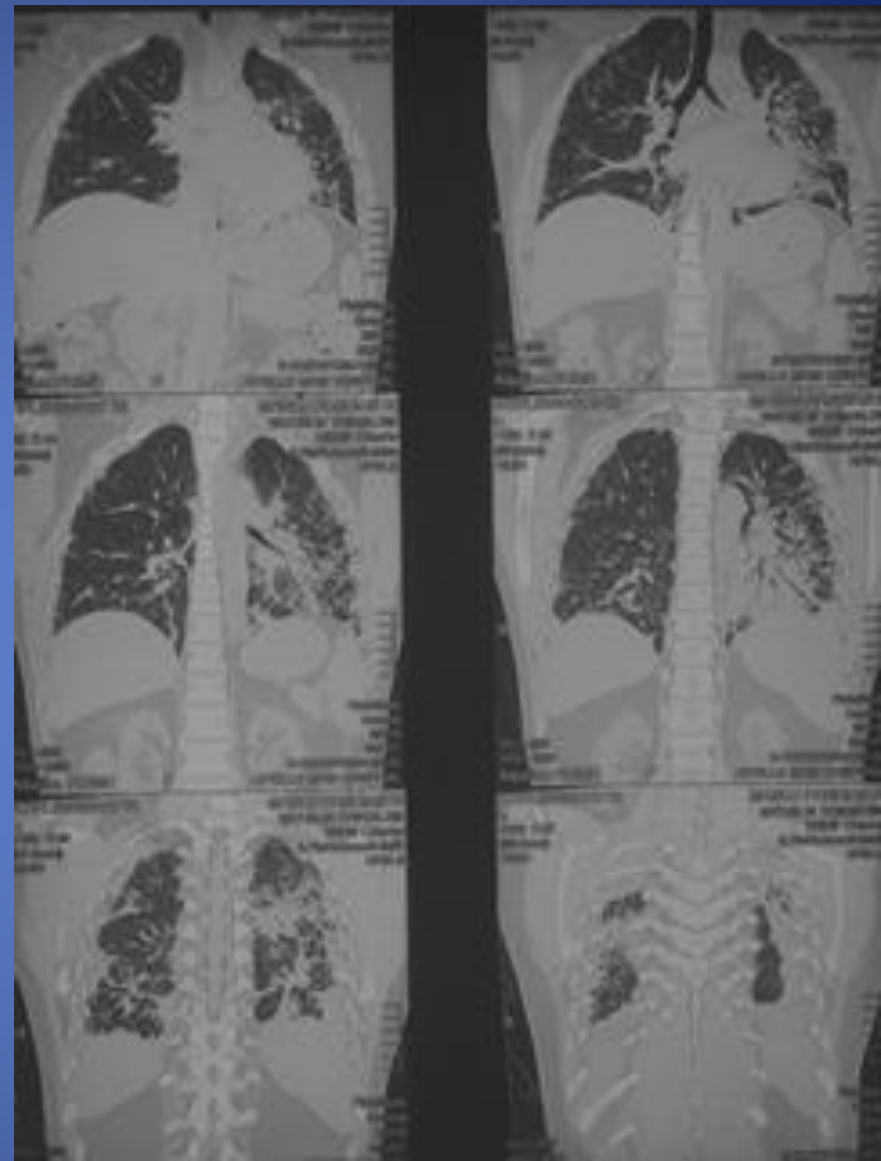
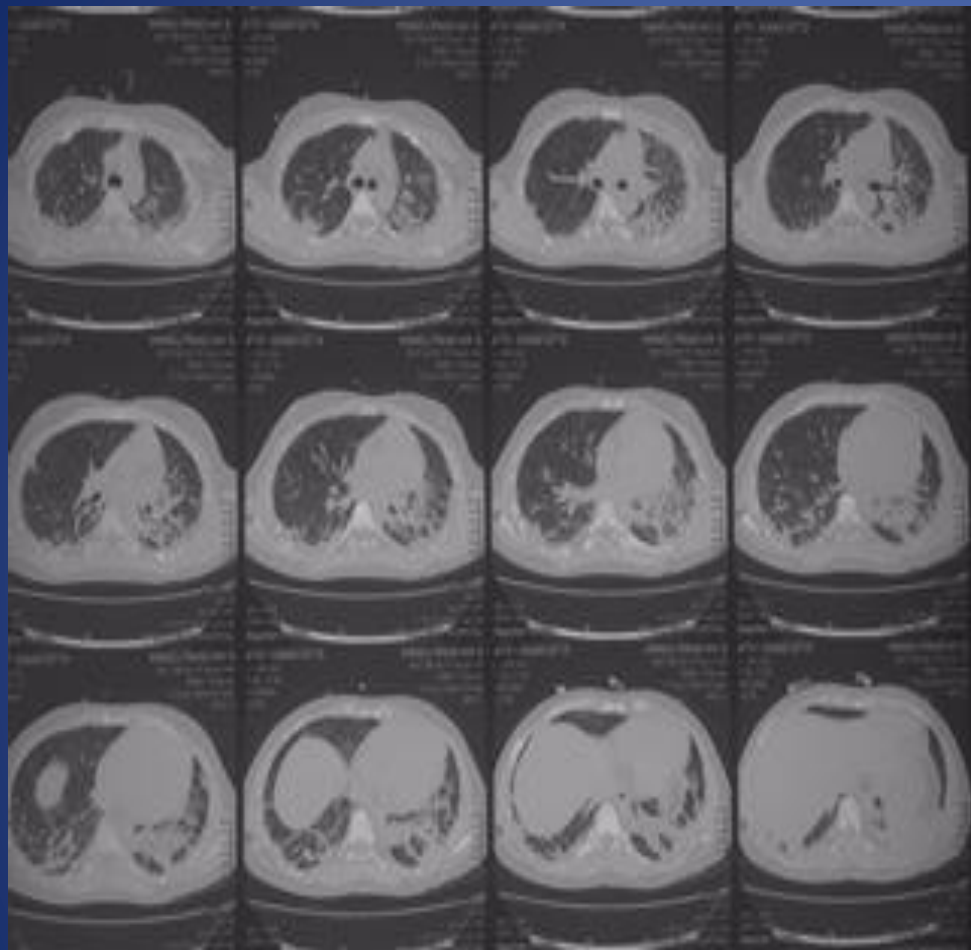
Day 3 - No improvement with antibiotics

Persistent Fever

Increasing respiratory distress

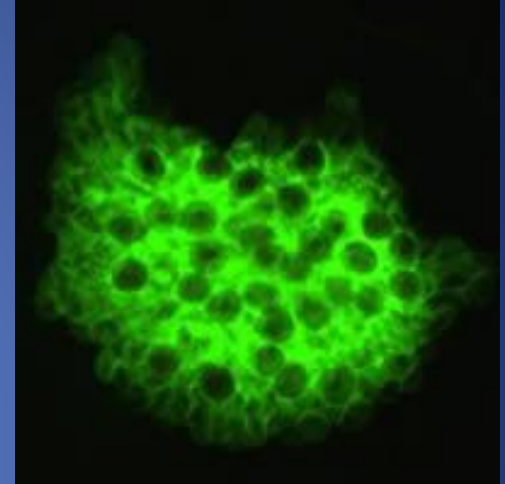
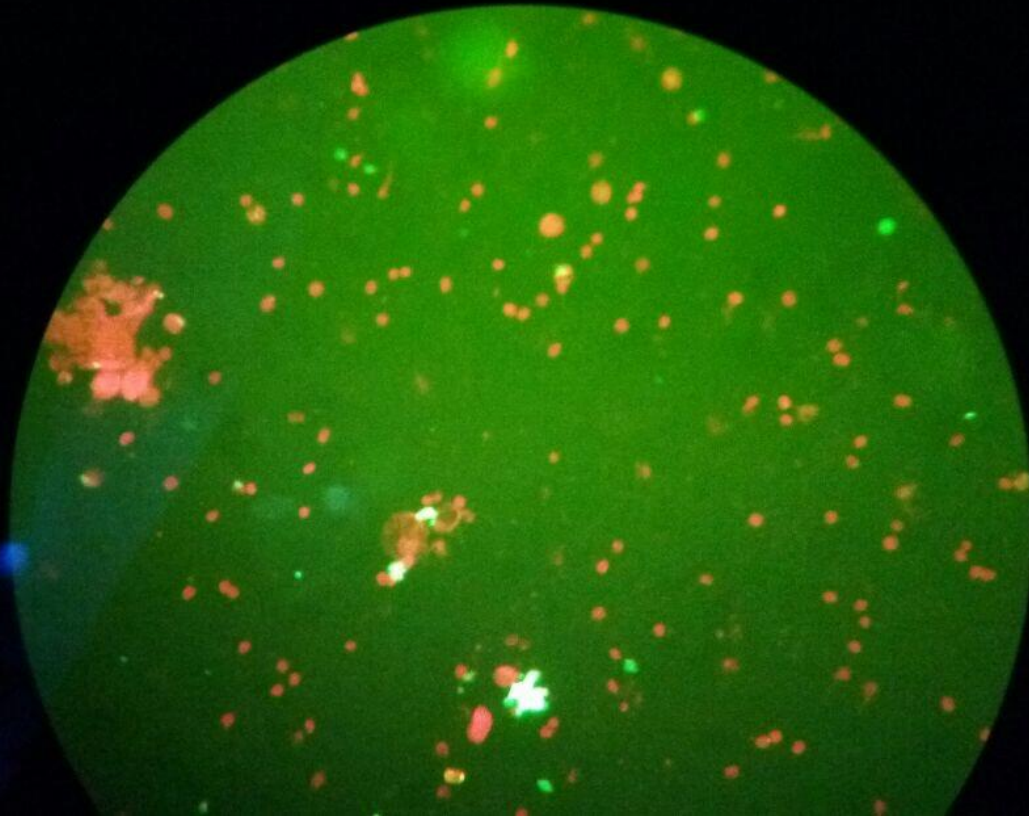
Urine Legionella Antigen - Negative

Respiratory Viral Panel - Negative



Diagnosis is...

- 1. pneumococcus
- 2. Nocardia
- 3. influenza
- 4. pneumocystis
- 5. Aspergillus



DFA test for Pneumocystis

PCP in the HIV negative host: risk factors

- hematologic malignancies (43%; predominantly NHL)
- solid tumors (25%)
- inflammatory diseases (20%)
- SOT (7%)
- Lymphocytopenia <500 (median total lymphocyte count 490 mm³.)
- Median CD4 count 120 cells/mm³
- 80% on corticosteroids (mean daily dose, 47 mg prednisone equivalent)
- 66% had received cytotoxic drugs (primarily cyclophosphamide or vincristine)
- 21% had received rituximab

Diagnosis of *P. jiroveci* pneumonia

- LDH usually elevated but non specific
- Silver stain or DFA on induced sputum or BAL
- PCR on BAL commercially available with 93% sensitivity and 91% specificity (J Clin Microbol 2011;49:1872)
- Quantitative PCR now available (*Clin Microbiol Infect* 2011 Oct; 17:1531)
- Elevated beta d glucan with cut off of 80 pg/ml has sensitivity of 92% and specificity of 65% (*Clin Infect Dis* 2011 Jul 15; 53:197)

- Steroids not beneficial in HIV negative PCP (Chest 2018 DOI: 10.1016/j.chest.2018.04.026)
- Sulfazalazine reduces risk (OR=0.08) (Semin Arthritis Rheum 2019 Feb)

Case

- 24/unmarried/male/office work/nellore-rural area
- CKD-?cause
- LDRT 6 months earlier from mother
- Induction – methyl pred 1gm
- Maintenance – TAC 4mg bd, MMF 360mg 2bd,pred 10mg
- Post transplant uneventful - DM new onset on OHA

- Azotemia on routine evaluation-
- Renal Biopsy- ATN, TAC levels in blood 24ng/ml
- TAC dose reduced to 1mg bd

10 days later

- Fever intermittent
- Cough with mucoid expectoration
- Right sided pleuritic chest pain
- Occasional blood stained sputum +
- DOE since 2 days
- No GI/GU/NS symptoms
- Exposure to paddy fields/construction site +
- No P/H/O TB or TB contacts

- Febrile(100.8 F),HR-120/min,BP-110/80mmhg.
- RR-28/min, Spo2-98% on room air, no LNE
- RS- BS reduced on right side,
- CVS
- GI WNL
- NS

- Hb -8.2gm%
- Wbc -5.9(N80/L6)
- Plt – 274
- Esr – 80
- Rbs 149
- Creat – 3.2
- Bil-0.8

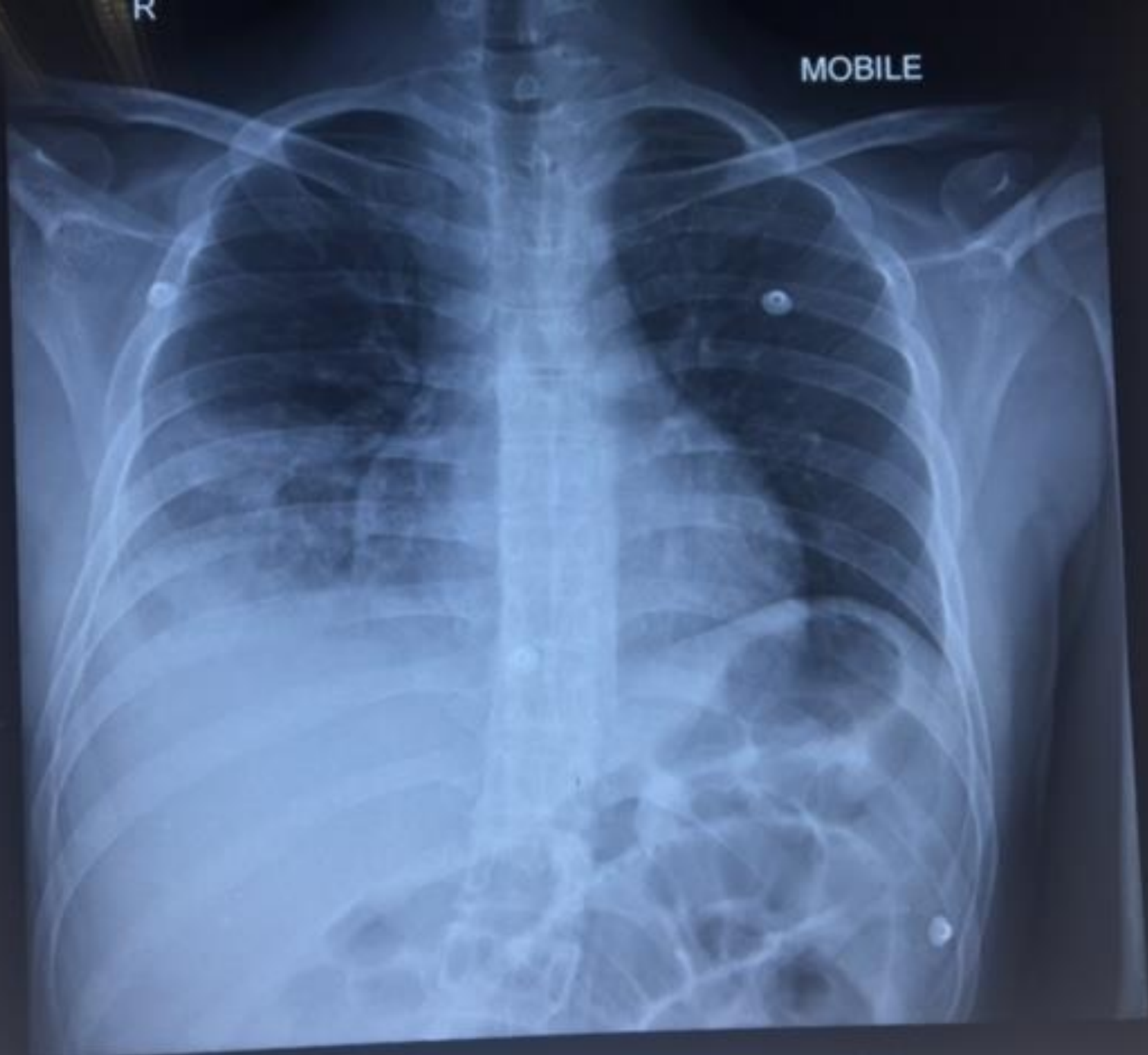
OT/PT-50/45

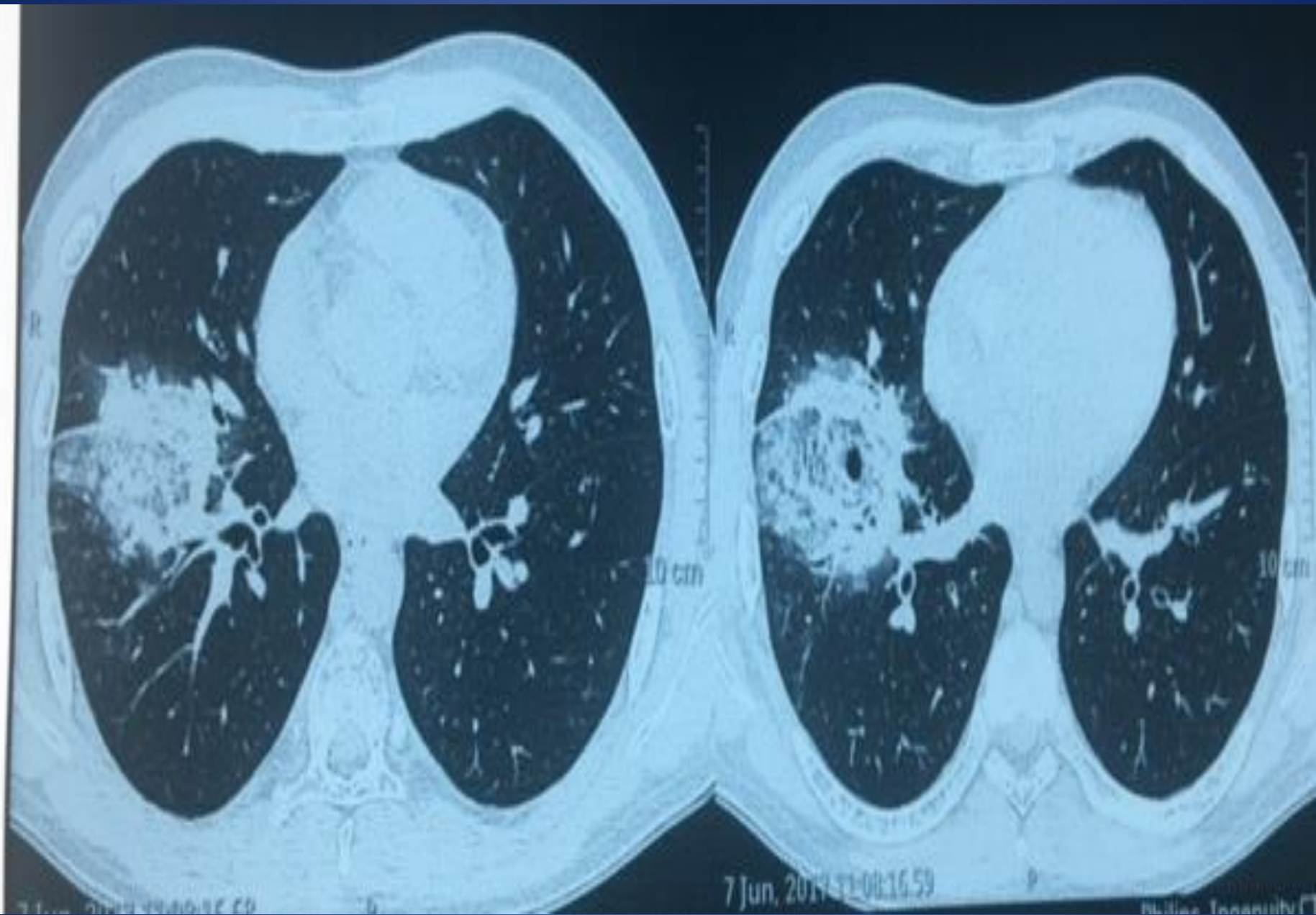
A/G-3.4/2.4

SAP- 180

urine R/M- 6-8puscells

R
MOBILE





7 Jun, 2017 11:08:16.59

7 Jun, 2017 11:08:16.59

7 Jun, 2017 11:08:16.59

Diagnosis is...

- 1. tuberculosis
- 2. melioidosis
- 3. E coli
- 4. mucormycosis
- 5. nocardiosis

- Bal for AFB/fungal stain negative
GM stain –many GNBs
Xpert Mtb neg
- Blood cs GNB in 2 sets

Blood cs

BAL cs

ANAEROBIC CULTURE AND SENSITIVITY [BLOOD] : (Culture)

Gram Stain	.
Identification Method	Conventional
Organism Name	<u>Ecoli</u>
Methodology Name	Kirby Bauer
Growth Observed	Yes
<u>Antibiotics Name</u>	<u>Results</u>
Cefotaxime	Resistant
Ceftriaxone	Resistant
Cefepime	Resistant
Cefoperazone+Sulbactam	Resistant
Piperacillin + tazobactam	Resistant
Aztreonam	Resistant
Imipenem	Resistant
Meropenem	Resistant
Ertapenem	Resistant
Doripenem	Resistant
Co-Trimoxazole	Sensitive
Gentamicin	Sensitive
Amikacin	

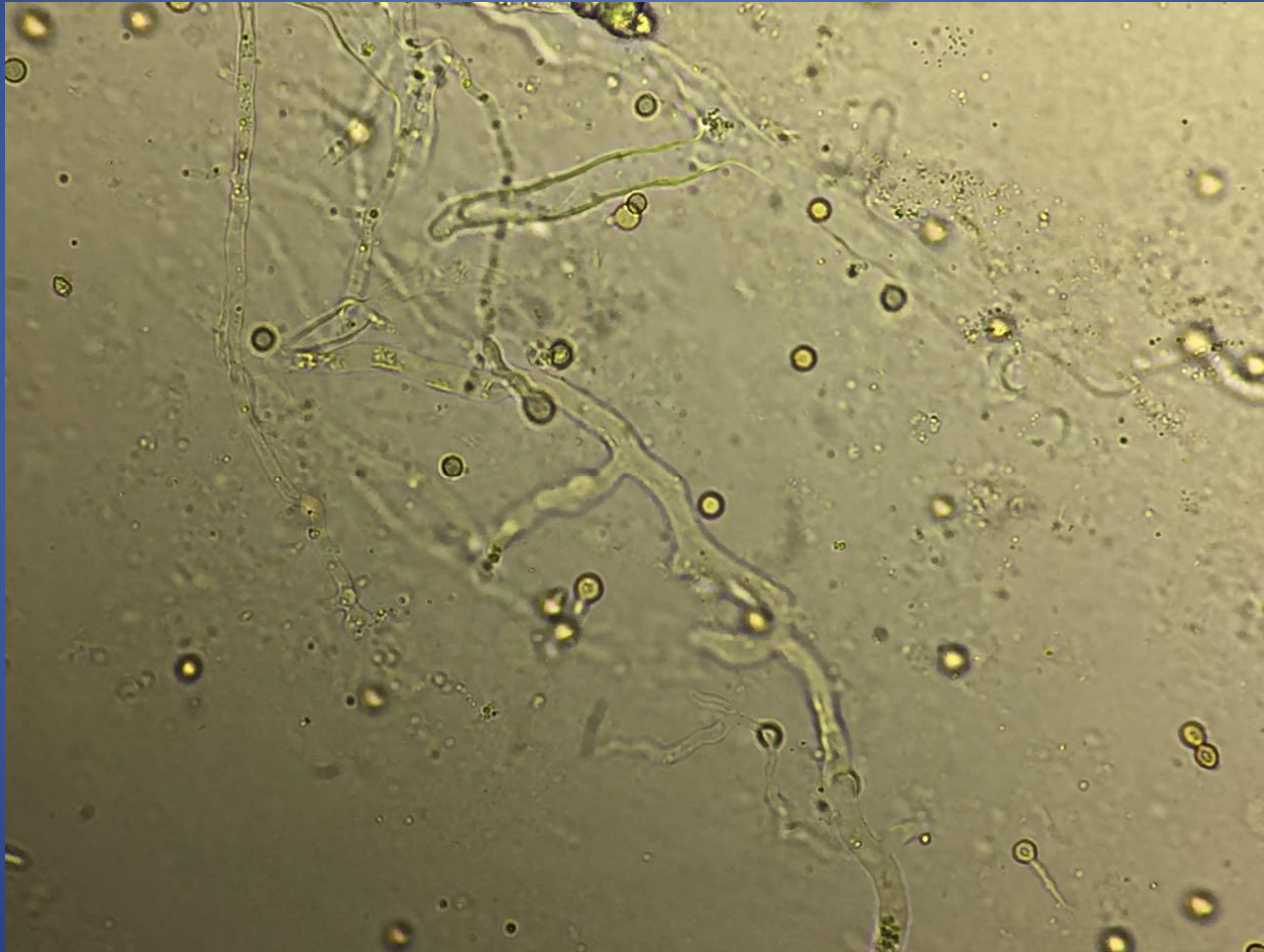
Colistin	Sensitive
Tigecycline	Sensitive
Ciprofloxacin	Resistant
Colistin	Sensitive

Colistin MIC: 0.5 g/l
 Imipenem MIC: >or=16.0 ug/ml (<or= 1 Sensitive)
 Meropenem MIC: >or=16.0 ug/ml (<or= 1 Sensitive)
 Doripenem MIC: >or=8.0 ug/ml (<or= 1 Sensitive)
 Minocycline: Sensitive
 ESBL and Carbapenemase: Positive

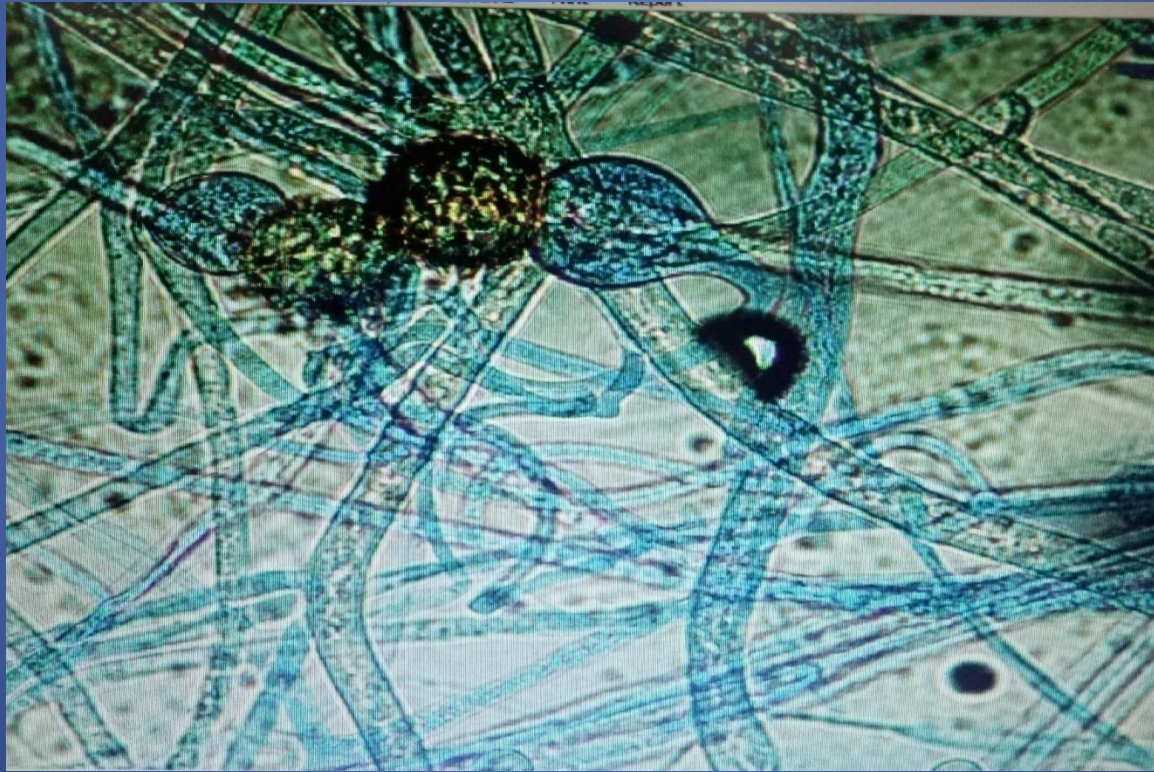
CULTURE AND SENSITIVITY [BRONCHIAL WASH] : (Culture)

Gram Stain	-Reported-
Identification Method	MALDI-TOF (Vitek MS)
Organism Name	<u>Ecoli</u>
Methodology Name	Kirby Bauer
Growth Observed	Yes
Colony Count	65,000col/ml
<u>Antibiotics Name</u>	<u>Results</u>
Cefotaxime	Resistant
Ceftriaxone	Resistant
Cefepime	Resistant
Cefoperazone+Sulbactam	Resistant
Piperacillin + tazobactam	Resistant
Aztreonam	Resistant
Imipenem	Resistant
Meropenem	Resistant
Ertapenem	Resistant
Doripenem	Resistant
Co-Trimoxazole	Sensitive
Gentamicin	

Wet mount of BAL wash



Lpcb



Culture plate



- Final diagnosis: cavitary pneumonia caused by CR E coli plus Mucormycosis

Fungal infections post solid organ transplant

- Risk:
 - small bowel (12%)
 - lung (9%)
 - liver (5%)
 - heart (3%)
 - kidney (1%)
- Invasive candidiasis (53%) > Aspergillosis (19%) > cryptococcosis (8%)
- Mucormycosis and Pneumocystis <3%

Invasive fungal infections in solid organ transplant recipients

- First month
 - candidiasis
- First 3 months
 - candidiasis and aspergillosis
- Thereafter
 - aspergillosis
 - Cryptococcosis
 - Mucormycosis

Case

20 yr old male / A P

Reccurent vomiting

Wt loss

Fatigue

1 month

Constipation

abdominal distention

4 -5 days

No fever/ cough/SOB

No Diarrhoea/malena or hemetemesis

No dysuria/hematuria

No h/o TB or TB contacts

History of LDLT 3 years ago

Donor – mother

Indication : cryptogenic cirrhosis

CMV IgG : positive

TB Quantiferon : negative

Vaccination : details NA

Immunosuppression:

Predisolone 20mg OD

MMF 500mg BD

Eevrolimus 5mg OD

Vitals normal

GPE : normal

Systemic examination : normal except for mild abdominal distention.

Investigations

Hb: 9

WBC: 7000/mm³ (N-90/E-2/L-7)

Platelets: 1.10lac/mm³

Creatinine: 1.2

BU: 58

Electrolytes : WNL

LFT: WNL

CT abdomen with contrast:

mild dilated fluid filled jejunal loops. Proximal and mid ileal loops mildly dilated. Distal ileum Collapsed

Rest normal study

□ Diagnostic laproscopy

Per OP findings were normal except for 1 cm lymph node which was biopsed, along with peritoneal Bx: report awaited.

Post op

Vitals stable

Bowel movements +

On RT aspiration

Post OP

New onset fever 102 F

Tachycardia HR 140/min

Drowsiness without FND

RS

CVS wnl

NS

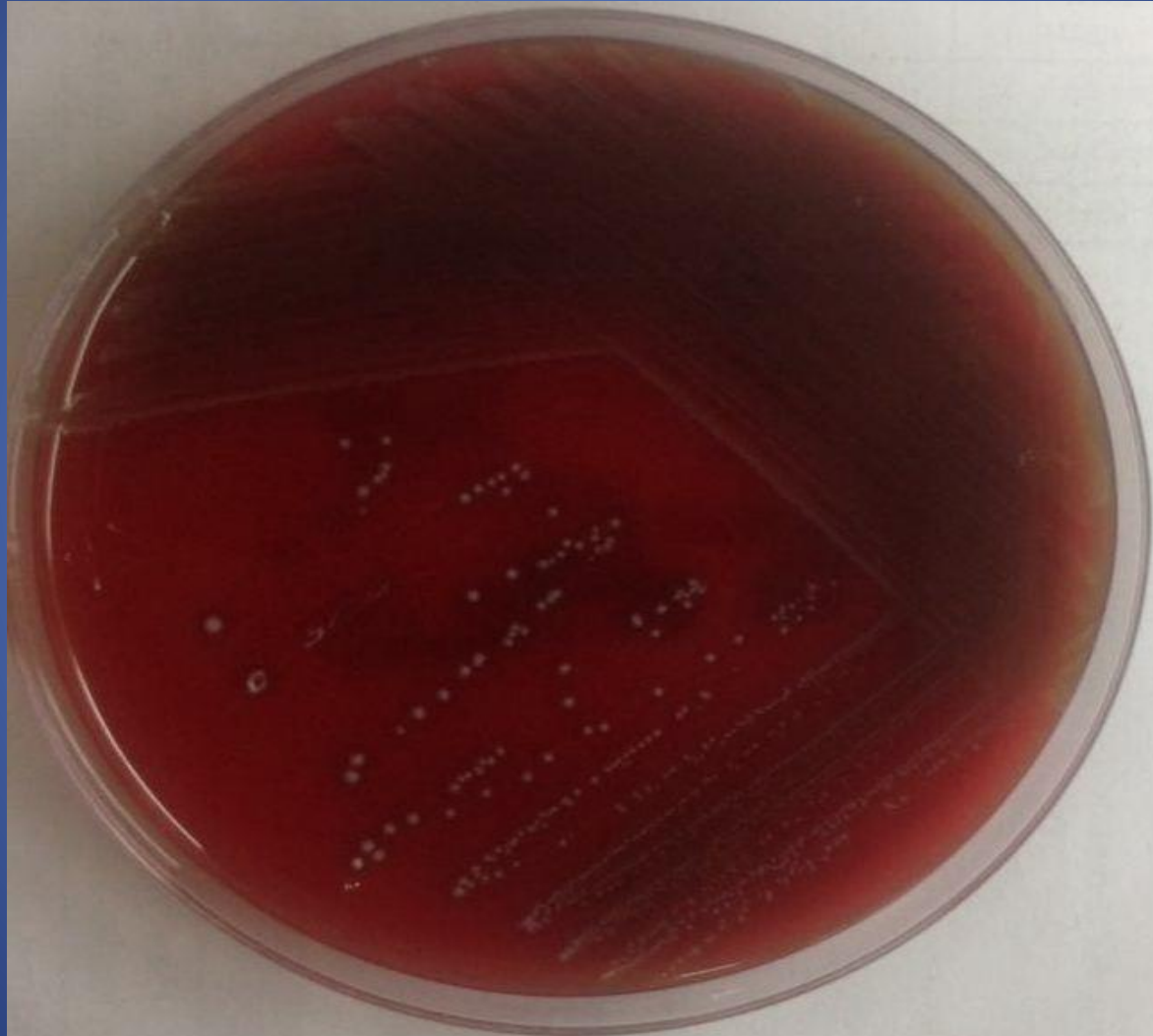
CSF- wbc 220(N⁶⁰/L⁴⁰)

rbc 50

protein 74

sugar 17

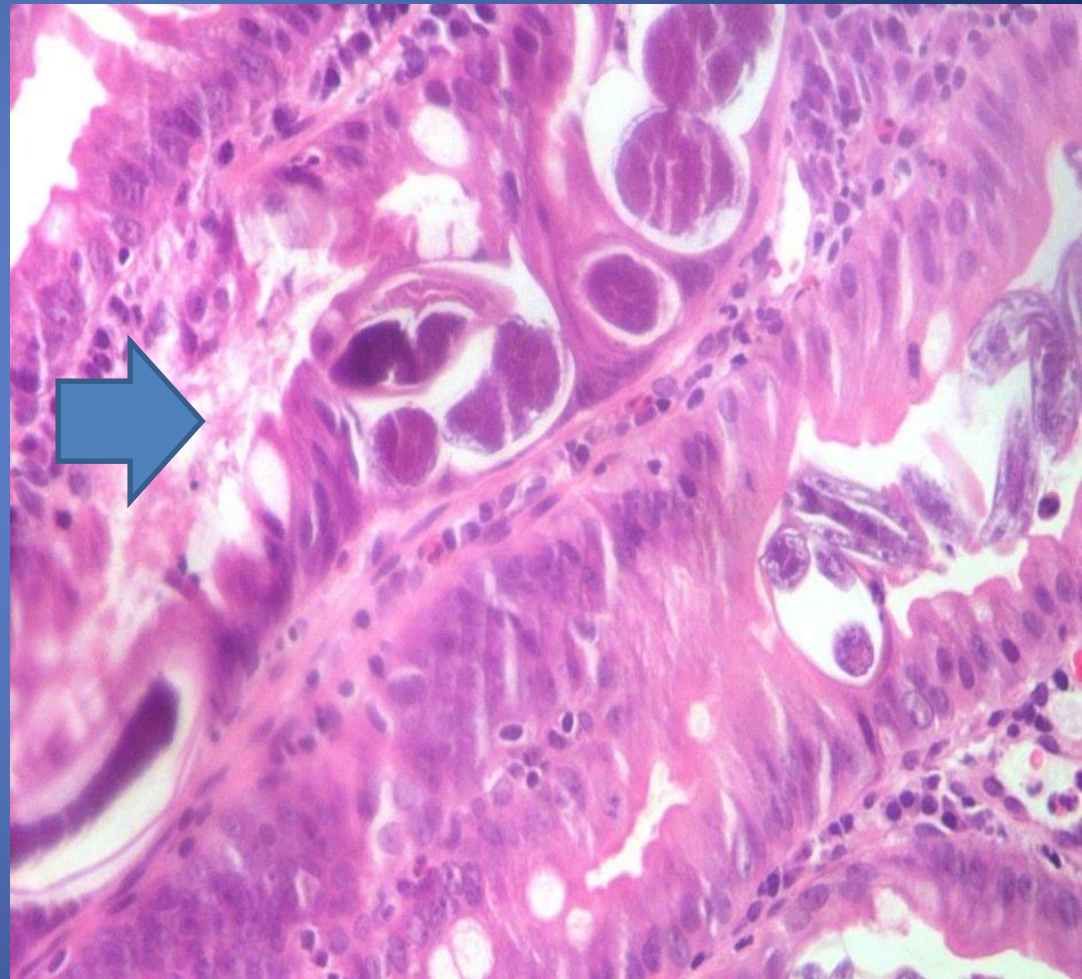
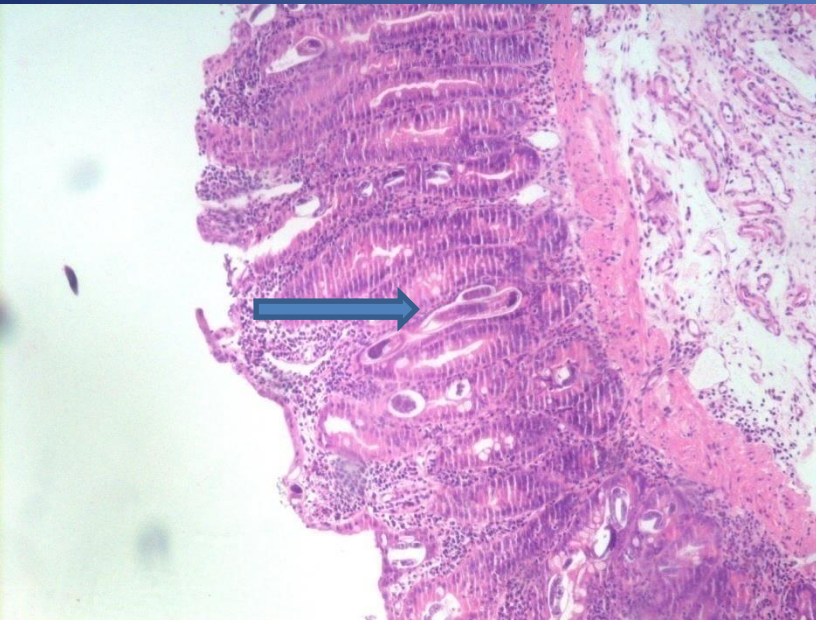
CSF and Blood culture



Diagnosis is..

- 1. meningococcus
- 2. pneumococcus
- 3. Staph aureus
- 4. Enterococcus
- 5. enterococcus

Duodenal HPE

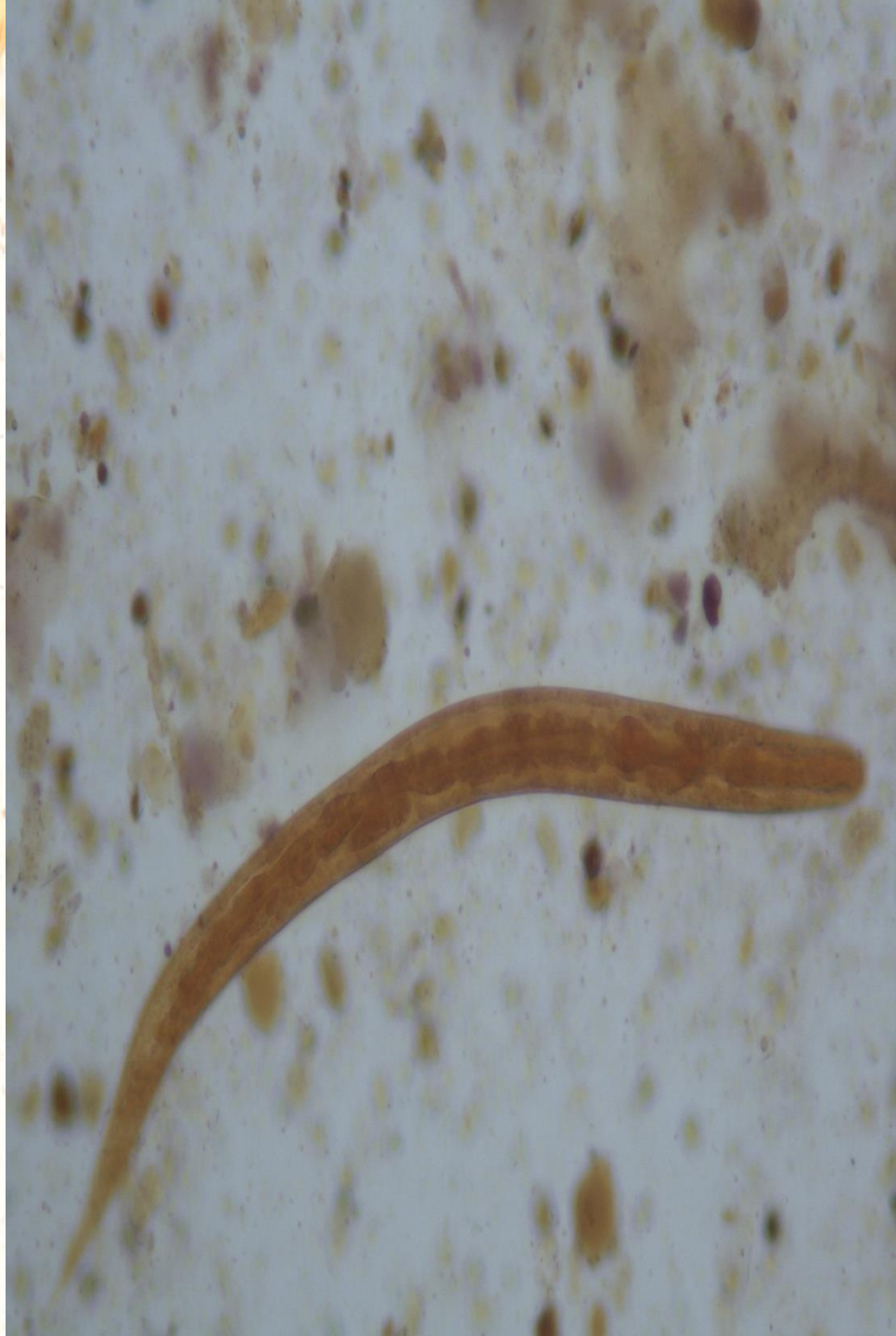
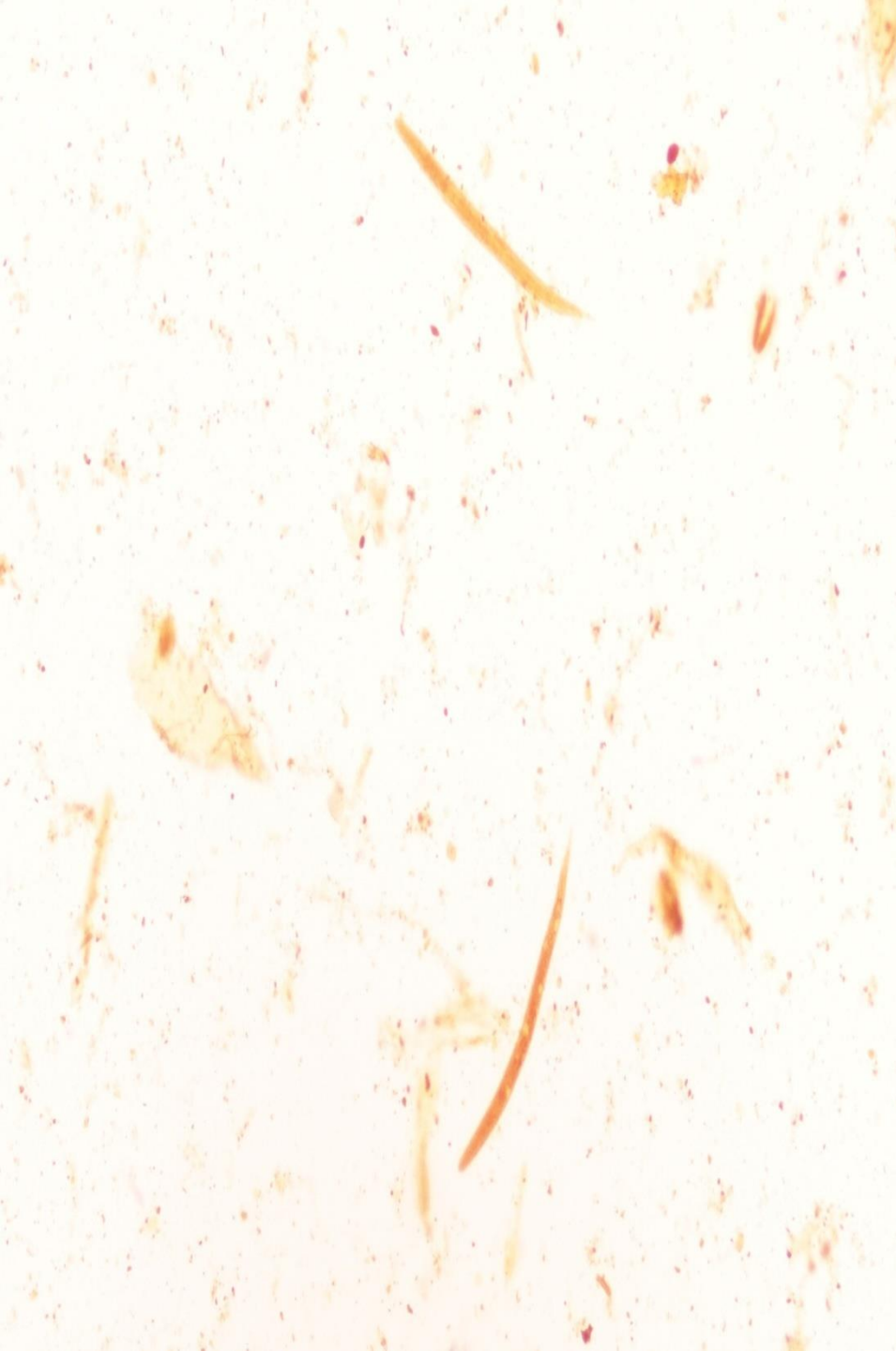


Predisposing GI disease is...

- 1. CMV
- 2. Strongyloides
- 3. TB
- 4. PTLD
- 5. cryptosporidiosis

Mesentric Lymphnode & duodenal HPE: nematode larva seen with numerous eosinophils

Peritoneal biopsy : rare acidophilic inclusions ?? CMV



Assesment

Strongyloidis stercoralis hyperinfection syndrome with secondary Enterococcal bacteremia & meningitis

CMV GI Disease

Enterococcal meningitis in association with *Strongyloides* hyperinfection syndrome

Kalpesh S Sukhwani^{1*}, Nitin Bansal², Mamta Soni³, Anand Ramamurthy⁴, Ram Gopalakrishnan⁵

Abstract

Introduction Strongyloidiasis can cause hyperinfection or disseminated infection in an immunocompromised host, and is an important factor linked to enterococcal bacteremia and meningitis.

Case reports We report two cases highlighting importance of suspecting *Strongyloides* hyperinfection syndrome in patients with enterococcal meningitis.

Conclusion Our cases highlight the importance of suspecting *Strongyloides* hyperinfection syndrome in cases of community acquired enterococcal bacteremia and meningitis.

Keywords *Strongyloides* hyperinfection syndrome, enterococcal meningitis, enterococcal bacteremia.

Case

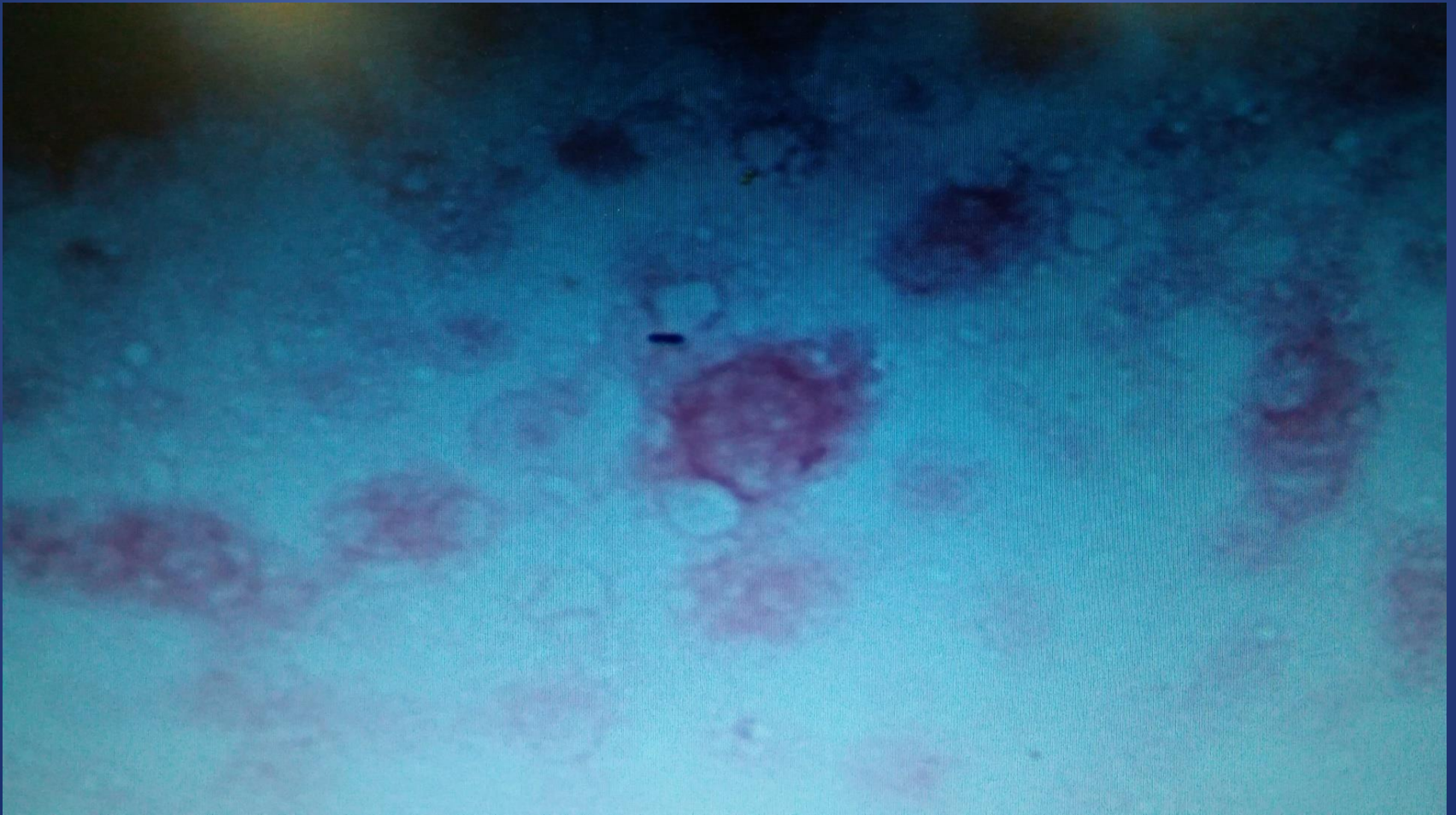- 62 year old
- Kidney transplant recipient on prednisone 7.5 mg and MMF 750mg od
- Fever, headache, vomiting - 1 day
- Abdominal TB 12 yrs ago, treated for 9 months.

- Confused
- Neck stiffness
- Right lateral rectus palsy

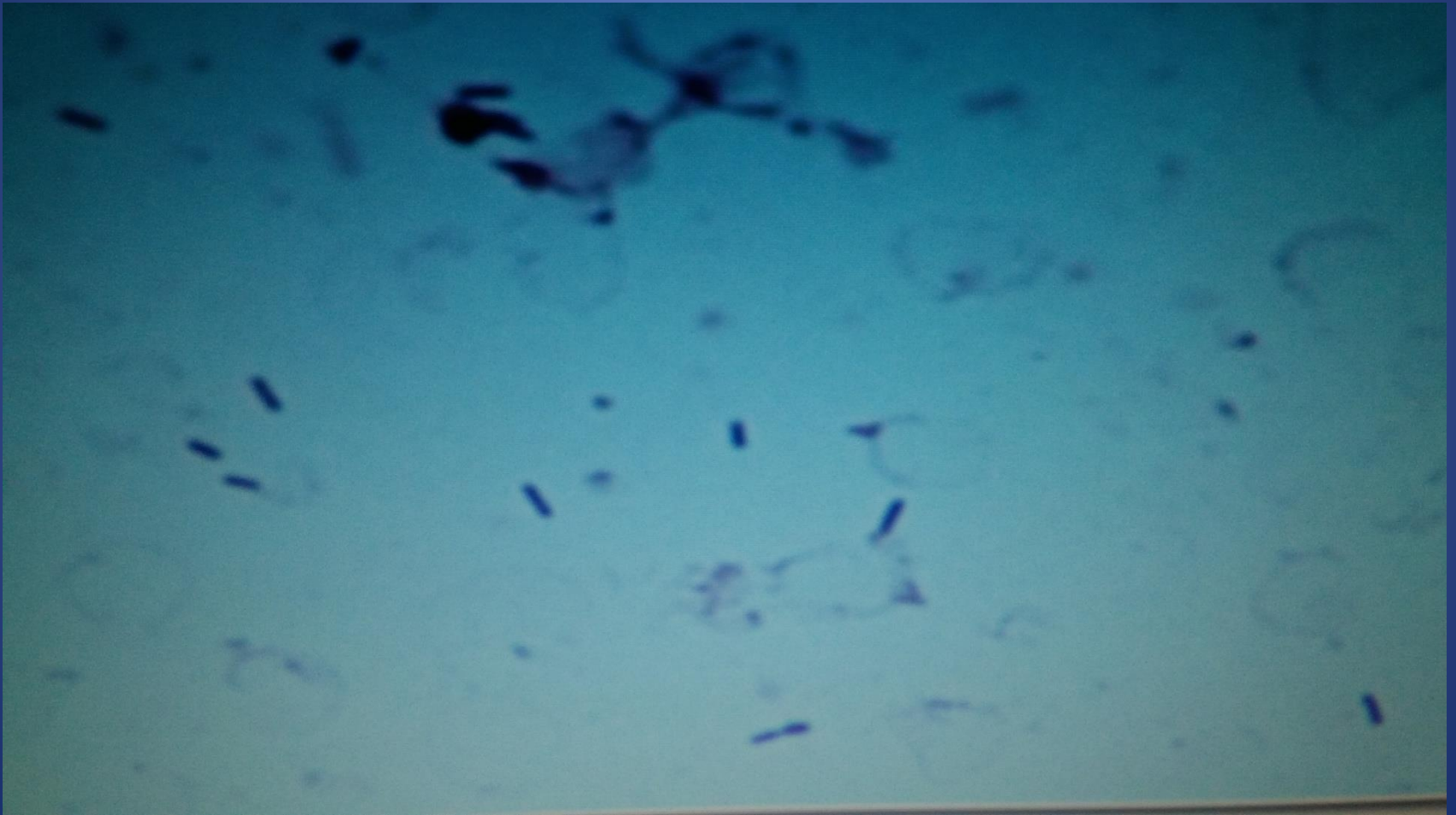
- Blood TC 18,200, P89, normal LFT
- Imaging- CT brain with contrast – normal
- CSF- TC 425, L92 P8, Glu 26 (196), Pro 230

- Xpert MTB, CrAg, HSV PCR neg, normal cytology

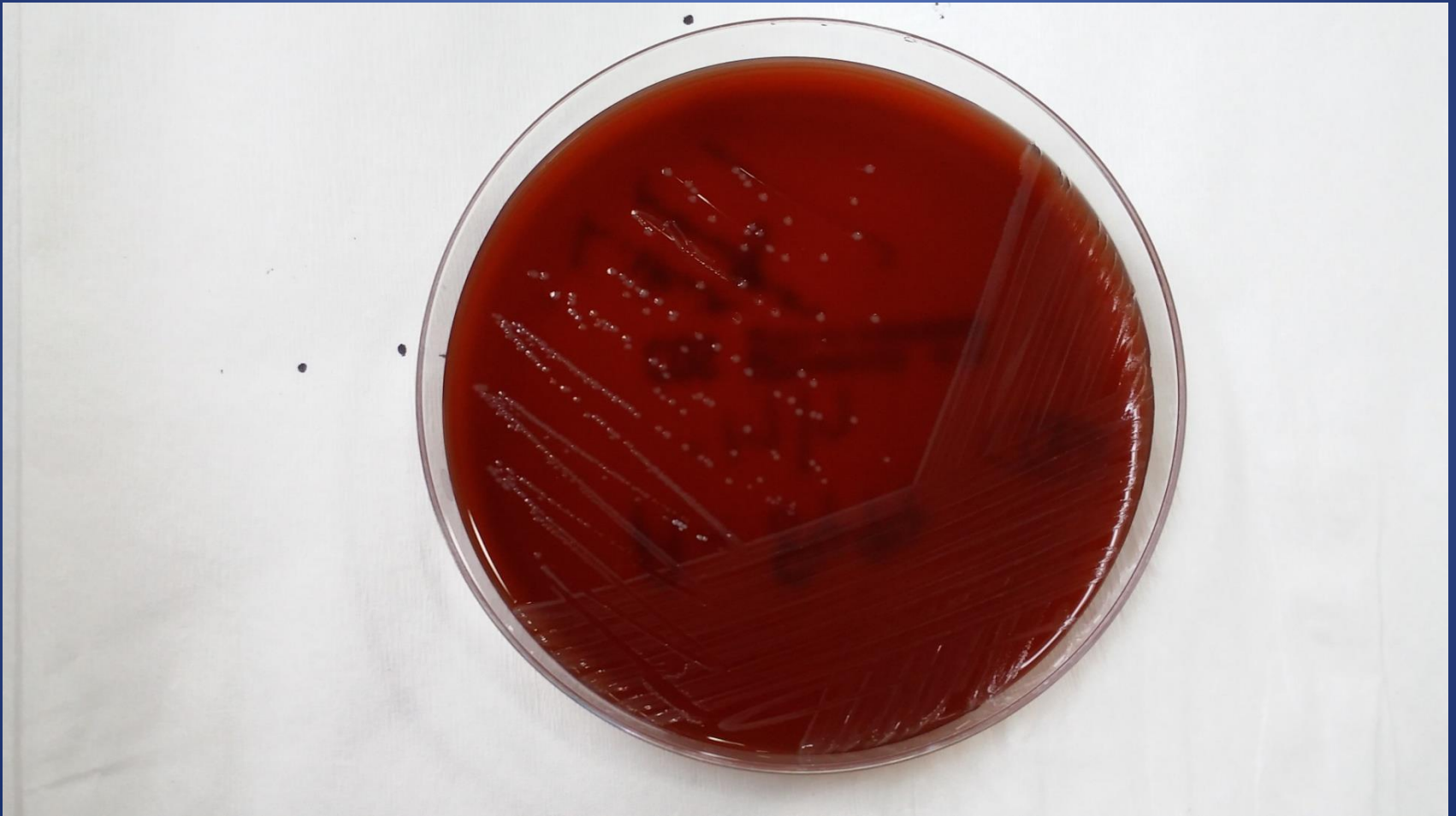CSF

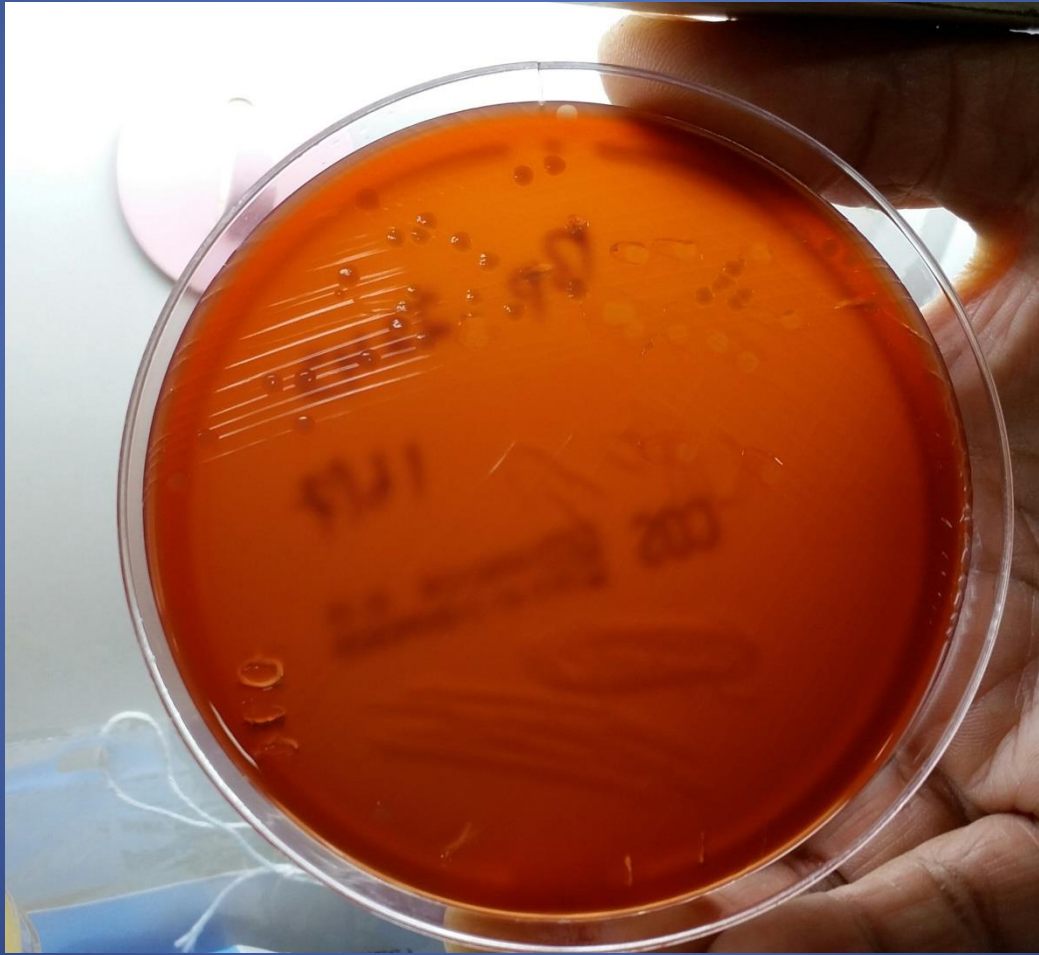


In blood



blood agar





Diagnosis is...

- 1. pneumococcus
- 2. Listeria
- 3. enterococcus
- 4. TB
- 5. meningococcus

Listeria in Adults – Truly Rare or Rarely Diagnosed in India?

Arjun Rajalakshmi¹, Ram Gopalakrishnan², P Senthur Nambi³, P Vishnu Rao⁴, V Ramasubramanian²

Abstract

Listeria monocytogenes is a facultative anaerobic intracellular Gram positive rod causing infection in pregnant women, extremes of age and immune-compromised hosts. In clinical specimens, the organisms may be gram-variable: laboratory misidentification of *L. monocytogenes* isolates as diphtheroids, streptococci, or enterococci is not uncommon and the isolation of a diphtheroid from blood or CSF should always alert the clinician to the possibility that the organism may be *L. monocytogenes*. The disease has rarely been reported in India in non-pregnant adults. We herein report four cases of *L. monocytogenes* infection in immune-compromised adults.

Case 2

A 65 year old lady with well controlled diabetes presented with acute onset fever, headache, vomiting and altered sensorium of 1 day duration. She was not on any immune-suppressants. There was neck stiffness and remainder of the examination was unremarkable. Her WBC was 11,000 cells/cumm. (polymorphs 70%). Liver and renal parameters were normal. Chest x-ray and brain imaging were

CNS syndromes

Meningo-encephalitis

- Cryptococcus
- TB
- Listeria

Mass lesions

- Nocardia
- Toxoplasmosis
- Tuberculoma
- Aspergillosis

Dementia

- PML

Case

62 Year male

1st Renal Transplant (Live Unrelated) - 2009

Recurrence of FSGS

2nd Renal Transplant - 2016 (September) – alemtuzumab per op

Prednisolone 20 mg od

Sirolimus 1mg bd

Septran 1 OD then ½ OD

Valgancyclovir

Loose stools - every day (5-6 episodes / day)
watery,
foul smelling,
no blood in stools ,
no abdominal pain

Almost a year

No h/o fever

Lost > 30 kg

Clinically Nil significant

Blood counts - normal

Admission creatinine - 3.4 (baseline – 1.5)

Extensively evaluated outside :

Multiple Stool analysis (including modified ZN) - negative

Colonoscopy twice - solitary colonic polyp found - snare polypectomy done

Capsule endoscopy – nil significant

OGD scopy once - antral erosions - duodenal biopsy - non specific duodenitis

Stool for strongyloides - negative

TTG antibody – slightly elevated -25.69 (<20 is normal)

Stool Calprotectin - upper limit of normal

Ferritin – normal

Vit B12 - normal

CMV Ig M – negative

CMV Ig G - Positive

Loperamide

Nitazoxanide

Metrogyl

Septran

Gluten free diet

Stopped Tacrolimus (? Tacrolimus induced diarrhoea)

Called on Day 3 of admission with a report of

Stool GI panel - EAEC positive

BK viruria + (in millions)

Urine for decoy cells +

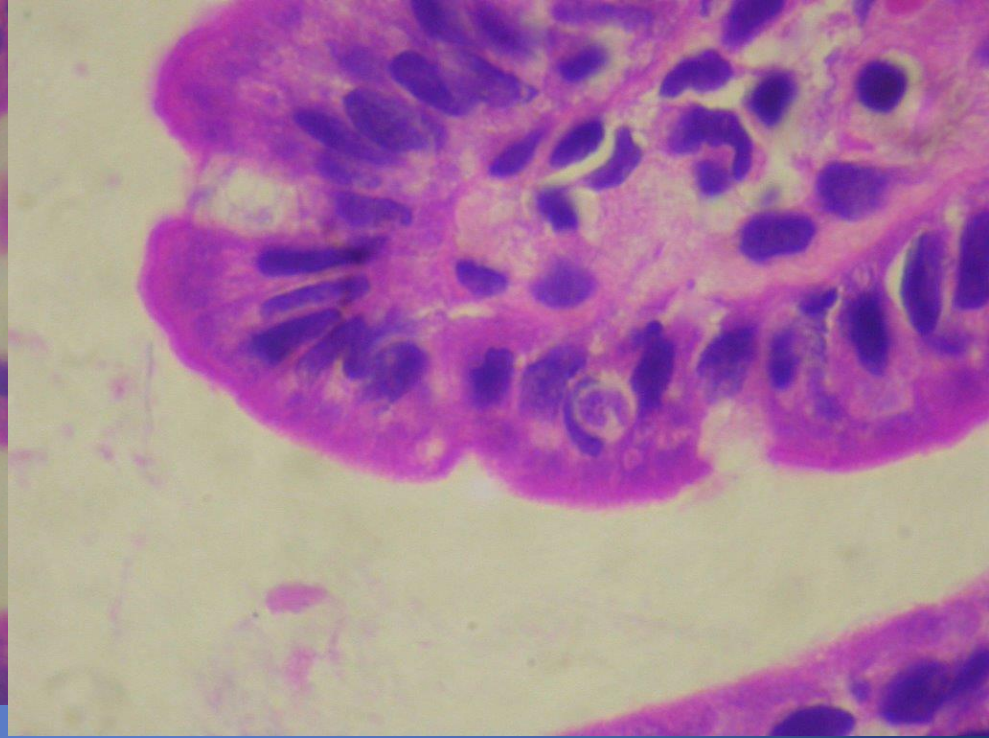
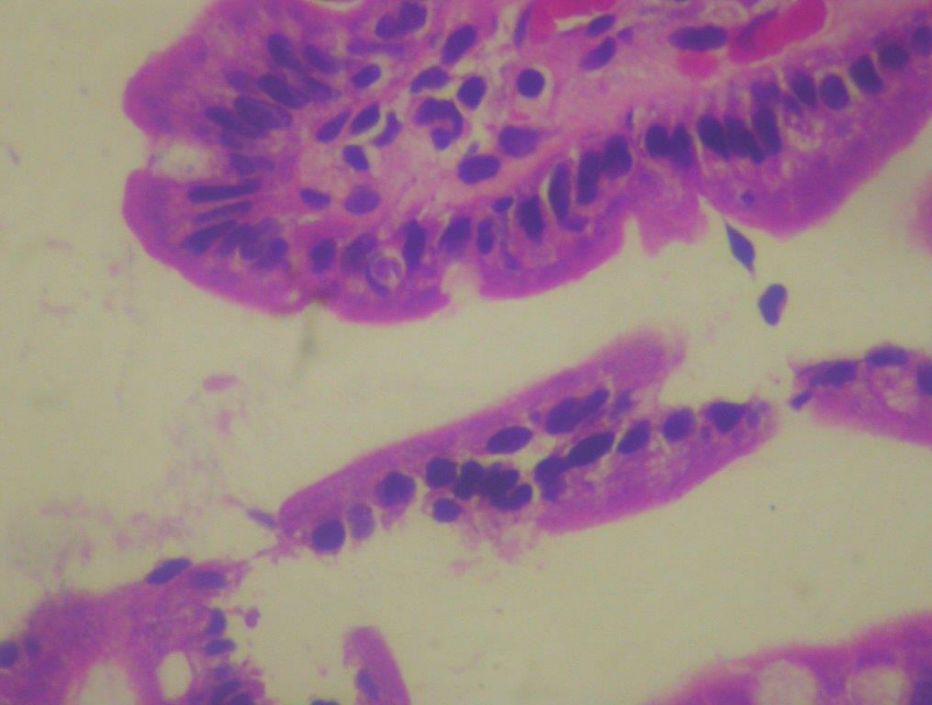
Plasma BK virus +

OGD SCOPY done :

showed antral erosions

small duodenal nodules

biopsy awaited



BIOPSY :

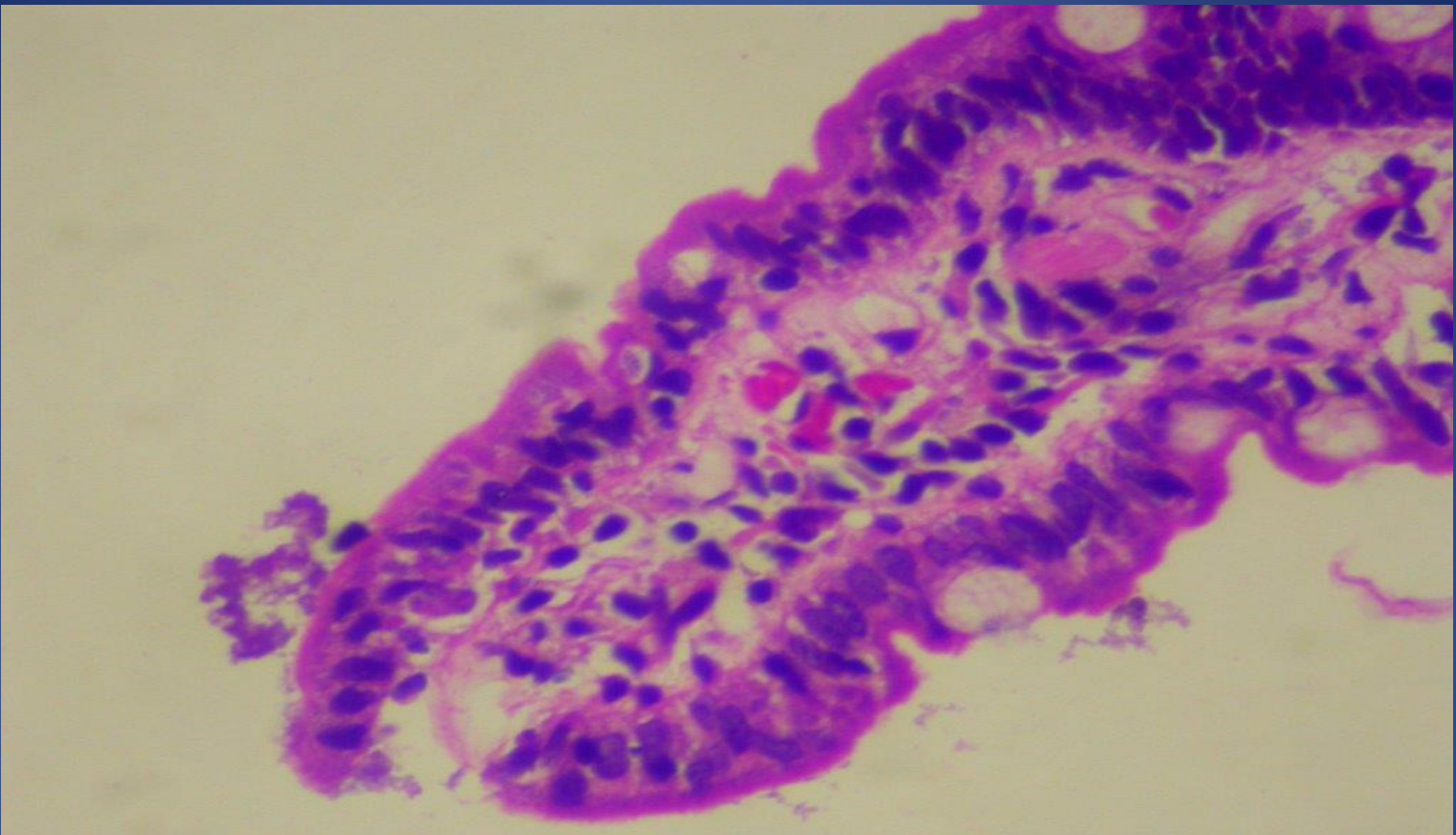
Fragments of duodenal mucosa with patchy blunting of the villi and with increase in intraepithelial lymphocytes.

The lamina propria also shows focal moderate increase in cellularity by lymphocytes, plasma cells and some eosinophils.

In the surface epithelium are rare foci of occasional structures seen with sub and paranuclear vacuoles -

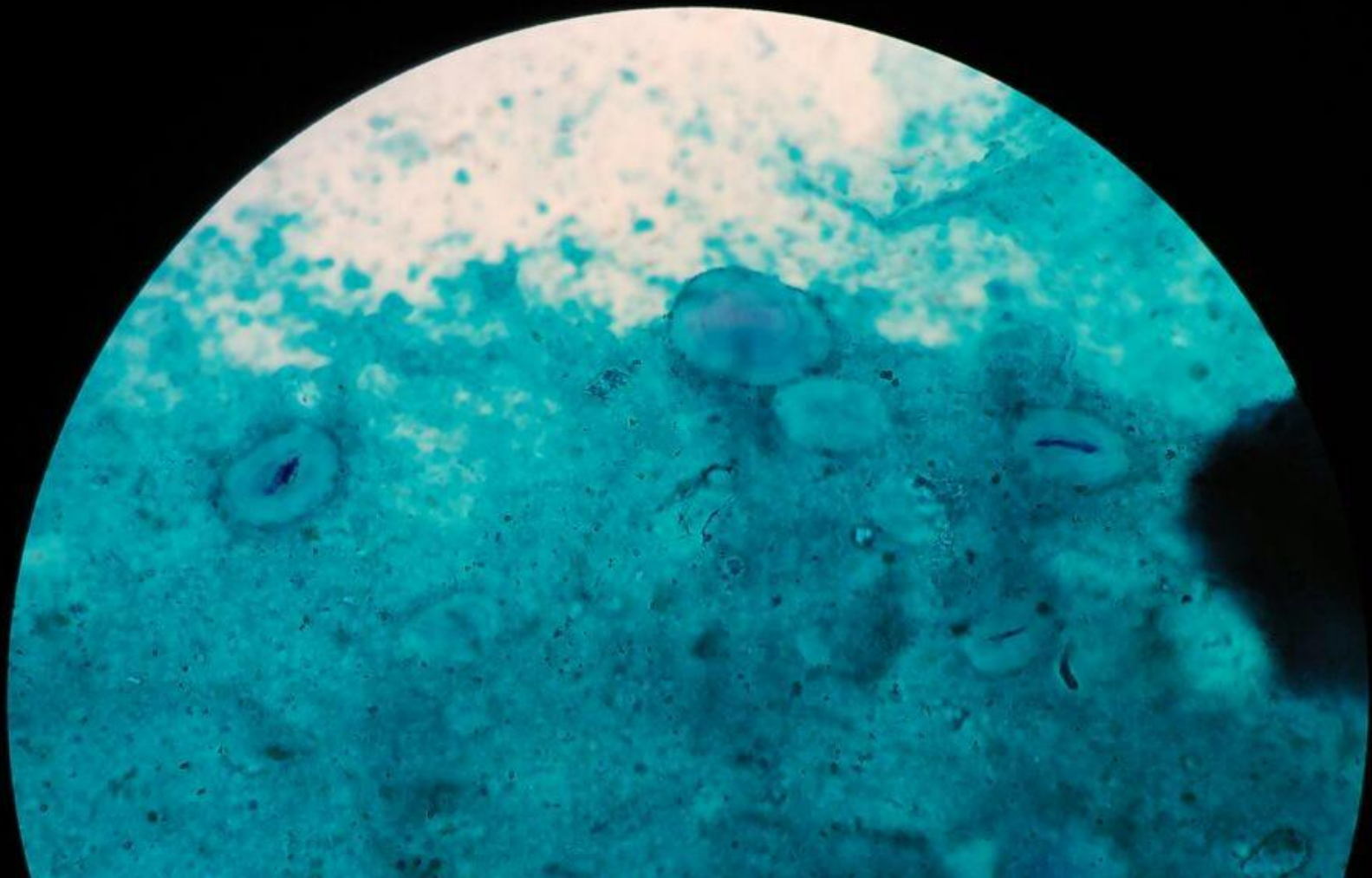
Diagnosis is....

- 1. Cryptosporidium
- 2. Cystoisospora
- 3. Giardia
- 4. Strongyloides
- 5. Microsporidiosis



A: Sections show fragments of duodenal mucosa with patchy blunting of the villi and with increase in intraepithelial lymphocytes. The lamina propria also shows focal moderate increase in cellularity by lymphocytes, plasma cells and some eosinophils. In the surface epithelium in rare foci occasional structures are seen with sub and paranuclear vacuoles - suggestive of the morphology of trophozoites of isospora and with a rare structure resembling a Schizontes. No definite merozoites are identified.

B: Sections show fragments of duodenal mucosa with mild increase in lamina propria cellularity by lymphocytes, plasma cells and a few eosinophils.



Final diagnosis: Isosporiasis

Started on cotrimoxazole and Albendazole

Diarrhea after solid organ transplant

- Majority of community- and hospital-onset diarrheal episodes had no identified etiology (60.9% and 75.9%, respectively; $P = .03$)
 - Were also self-limited (91% and 91%, respectively)
 - Approximately one-third had infectious etiologies identified, consisting predominantly of *C. difficile*, norovirus, cytomegalovirus, and bacterial enterocolitis.
 - Protozoan causes were rarely seen
 - Did not use molecular methods for diagnosis
- Use of multiplex molecular panels increases yield from 23% to 72%
- Norovirus may cause chronic and often relapsing diarrhea.
 - Treated with nitazoxanide, intravenous immunoglobulin, and reduction in immunosuppression (*Transpl Infect Dis* 2017 Apr 19:e12674)

Clin Infect Dis. (2015) 60 (5):729-737.

Clin Infect Dis. (2015) 60 (5):738-740.



Utility of multiplex polymerase chain reaction (PCR) in diarrhea—An Indian perspective

Balavinoth Ramakrishnan¹ · Ram Gopalakrishnan¹ · P Senthur Nambi¹ · Suresh Kumar Durairajan¹ · R Madhumitha¹ · Anil Tarigopula² · Chitra Chandran² · V Ramasubramanian¹

Received: 30 March 2018 / Accepted: 12 August 2018

© Indian Society of Gastroenterology 2018

Abstract

Background Infective diarrhea causes morbidity worldwide. Polymerase chain reaction (PCR)-based pathogen diagnostics of diarrheal stool specimens are shown to be highly sensitive and rapid as opposed to conventional diagnostics.

Methods We analyzed the performance of FilmArray gastrointestinal (GI) panel, one such multiplex PCR test, on stool specimens in patients presenting with diarrhea to our hospital from March 2016 to September 2017 and compared the results with conventional diagnostic tests.

Results A total of 106 patients were included. The panel detected at least one target in 54 out of 106 patients (50.9%) with results available on the same day. Multiple targets were detected in 26 out of 54 patients who tested positive (48.1%). Bacteria as an isolated etiology for diarrhea was present in 34 patients (62.9%), viruses (16.7%, nine patients), parasites (7.4%, four patients), and multiple pathogens in seven patients (12.9%). Enteroaggregative *Escherichia coli* (EAEC) was the commonest pathogen detected (in 23, 24% patients). Conventional diagnostic investigations, undertaken in 68/106 (64.1%) patients were positive in 12 (17.65%) as compared to 54/106 (50.9%) ($p < 0.0001$). Conventional investigations detected a pathogen not included in the study panel in 11 of 52 patients (21.1%).

Conclusion FilmArray multiplex PCR panel detects a wide array of GI pathogens including viruses and co-infections at a shorter time with more sensitivity compared to conventional diagnostics. Henceforth, it may facilitate treatment decisions, isolation policy, and antimicrobial stewardship in patients with diarrhea requiring hospitalization.

Case

- 18/F from Chennai
- Diagnosed ALL after presenting with intra-cranial bleed 8 months ago
- Underwent ALL induction but relapsed, re-induced with FLAG-IDA regimen, achieved remission
- Had pulmonary nodules during admission that were empirically treated with voriconazole, clinically/ radiologically better
- Discharged, readmitted for allo-PSCT
- Underwent PSCT 4 months ago, discharged after engraftment on posaconazole and cotrimoxazole prophylaxis
- Developed CMV reactivation day 60, viral load became undetectable on iv ganciclovir, switched to oral valganciclovir maintenance
- Improved with normalization of counts and weight gain at day 90, with bone marrow chimerism test showing 100% donor cells

Course after transplant

- At day 85, starts developing wasting syndrome with low grade fever (profound anorexia without vomiting or diarrhea, weight loss of 20 kg)
- Exam: weight 30 kg (pre transplant weight 60 kg), otherwise NAD
- Progressive pancytopenia (Hb=6.6, WBC=800, platelets <10,000) at day 105
- Medications: prednisone 20 mg, tacrolimus
- Develops renal dysfunction, initially fluid responsive but later AKI requiring dialysis

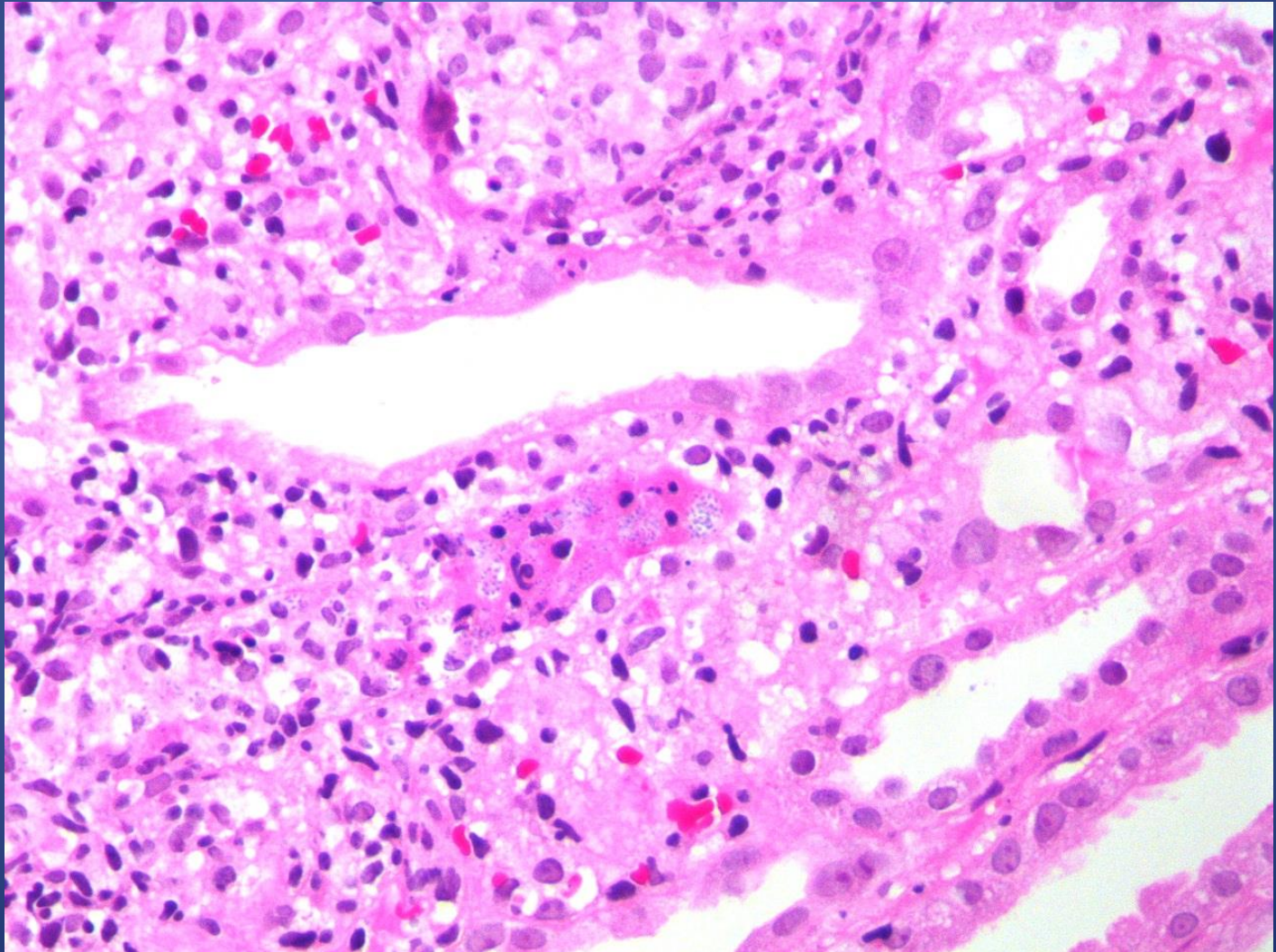
Workup

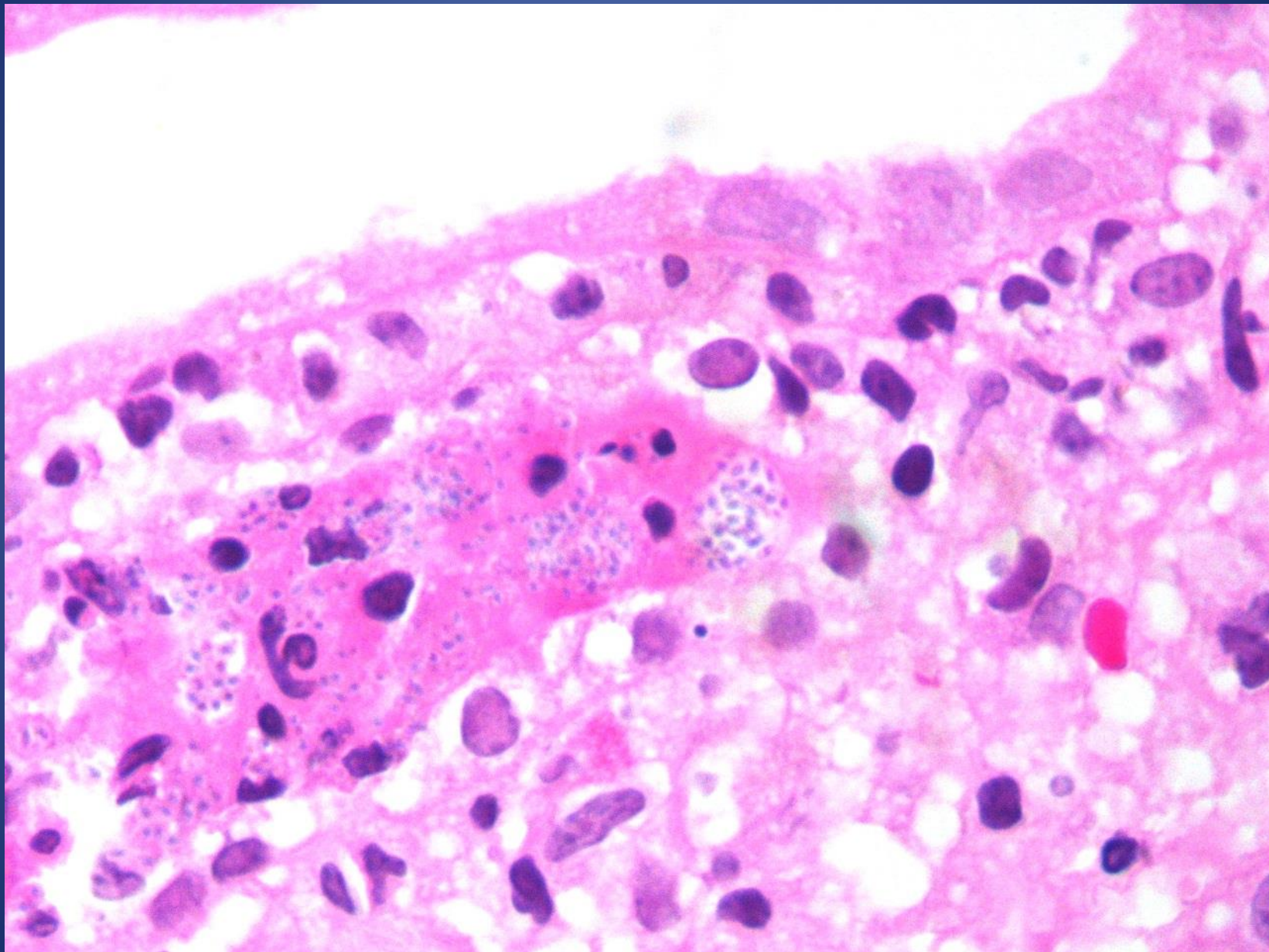
- Blood cultures negative
- PET-CT scan: pulmonary scars, no increase in previously seen nodules
- CMV/EBV/adenovirus viral load all negative
- Bone marrow exam twice: hypo-cellular, special stains for pathogens negative
- EGD to duodenum normal
- LFT normal
- Serum ferritin: 20,000-30,000

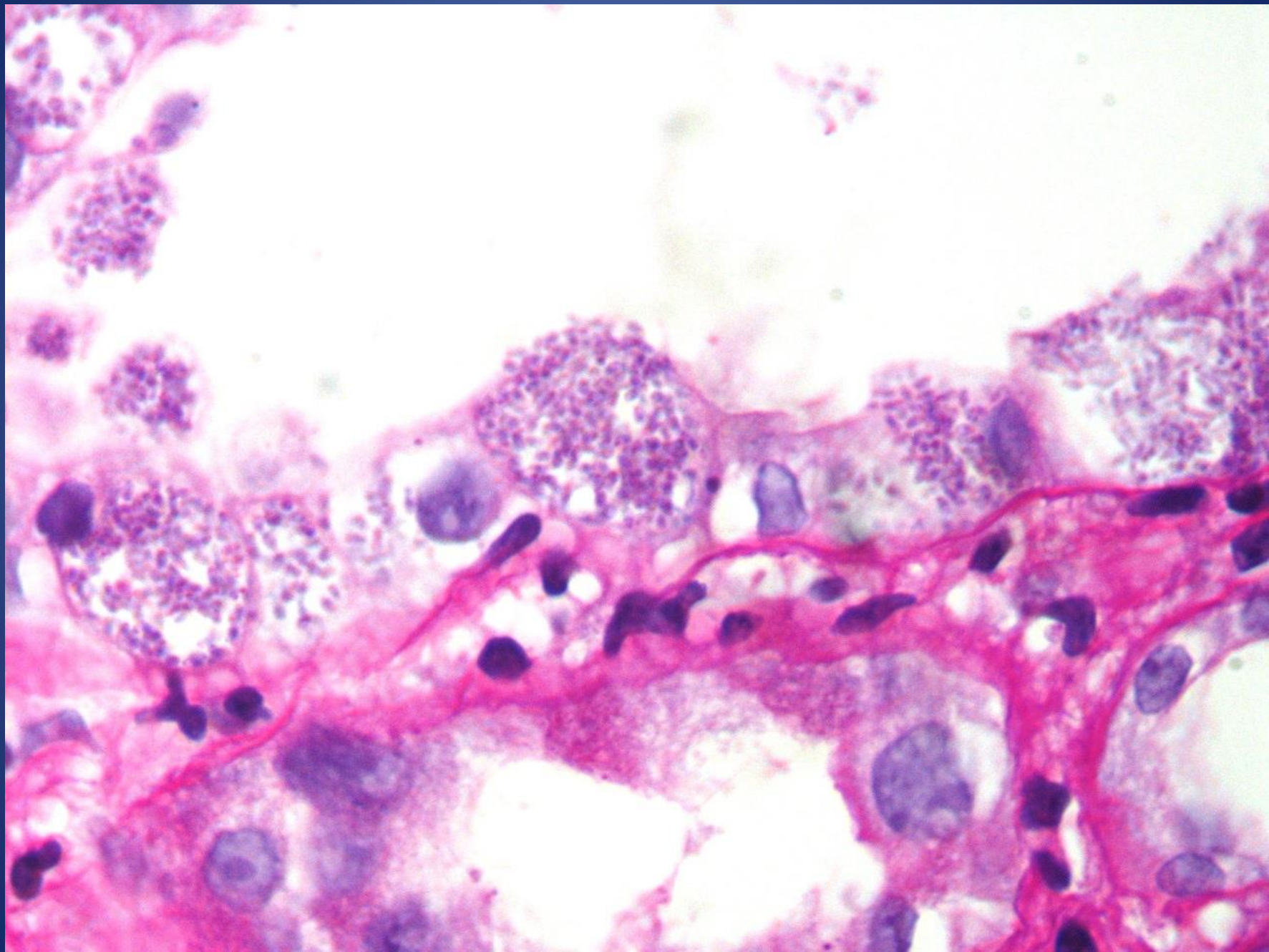
Diagnosis is...

- 1. CMV
- 2. Microsporidiosis
- 3. Histoplasmosis
- 4. Leishmaniasis
- 5. Disseminated TB

Kidney biopsy







Microsporidia

- Intracellular protozoa that cause infections patients with T cell mediated immune deficiency
- Enterocytozoon bienersi typically causes diarrhea and wasting in AIDS patients: usually does not respond to albendazole, may respond to fumagillin
- Encephalitozoon species typically cause disseminated disease, responds to albendazole
- Several case reports in transplant recipients

Disseminated Microsporidiosis in an Immunosuppressed Patient

Eric G. Meissner, John E. Bennett,
Yvonne Qvarnstrom, Alexandre da Silva,
Emily Y. Chu, Maria Tsokos,
and Juan Gea-Banacloche

We report a case of disseminated microsporidiosis in a patient with multiple myeloma who had received an allogeneic stem cell transplant requiring substantial immunosuppression. The causative organism was identified as *Tubulinosema acridophagus*, confirming this genus of microsporidia as a novel human pathogen.

Microsporidia fungi are human pathogens known for causing diarrheal illness in persons infected with HIV; however, there is growing awareness of their involvement in other cases of host immunosuppression. A case of *Tubulinosema* sp. microsporidian myositis was recently reported in a patient with chronic lymphocytic leukemia (1). We describe a second case of disseminated microsporidiosis caused by a *Tubulinosema* sp. in an immunosuppressed patient who received an allogeneic stem cell transplant for multiple myeloma.

The patient received a 7/8 HLA-matched allogeneic peripheral blood SCT (with a single mismatch at the DRB1 locus) from an unrelated donor. Her clinical course was complicated by vancomycin-resistant *Enterococcus faecium* bacteremia, meningitis, and concomitant noncommunicating hydrocephalus and retinal hemorrhages. The bone marrow did not reconstitute, and 35 days after the initial transplant, the patient received a second SCT from the same donor after a conditioning regimen with antithymocyte globulin. Engraftment took place on day 49, 14 days after the second transplant. Progressive respiratory failure and pulmonary infiltrates had developed over the preceding week despite administration of broad-spectrum antimicrobial drugs. Results of a bronchoscopy on day 49 showed diffuse alveolar hemorrhage and did not identify a pathogen. Treatment with activated factor 7 and corticosteroids was given with some clinical improvement as well as improvement shown on chest radiograph.

A second bronchoalveolar lavage (BAL), performed on day 64, again showed diffuse alveolar hemorrhage and absence of pathogens. The patient received a second course of corticosteroids and activated factor 7. On day 77, an ophthalmologic examination was performed during a routine follow-up, and new retinal lesions suggestive of candida chorioretinitis were seen. Liposomal amphotericin B was substituted for prophylactic anidulafungin, and an intravitreal injection of amphotericin B was given for a subfoveal lesion.

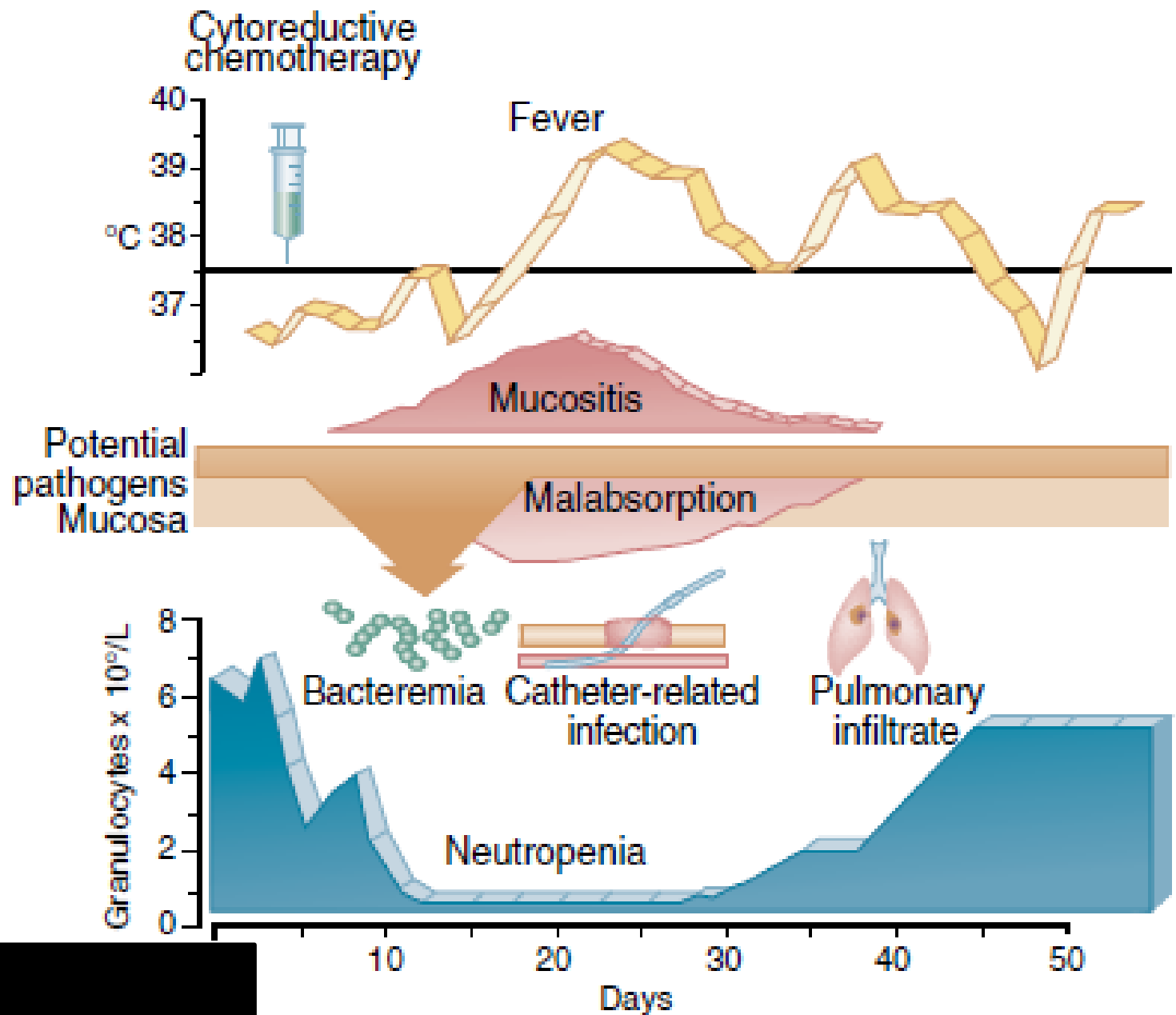
At this time, the patient also had increasing hyperbilirubinemia and elevation of liver aminotransferases, together with diarrhea, abdominal distension, and new ascites. Graft-versus-host disease of the gut and liver was

Treatment

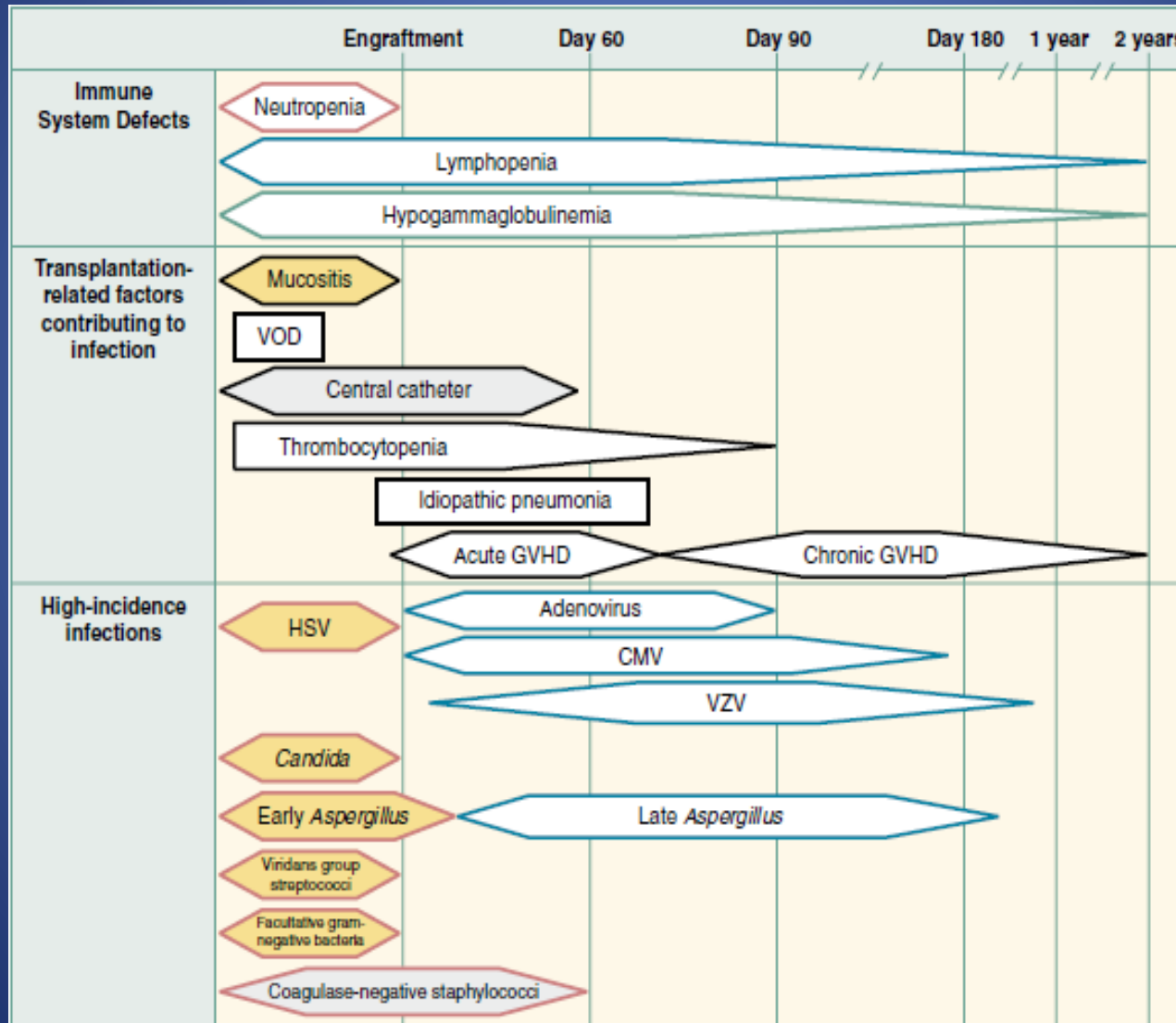
- Presence of microsporidia in urine indicates an albendazole responsive species
- Patient was started on albendazole 400 mg bd
- Immuno suppression was minimized
- Improved and discharged

Hematopoietic cell transplantation

- Conditioning regimen eradicates patient's marrow
- Autologous HCT
- Allogeneic HCT
 - Additional issue of GVHD
 - Medications to prevent GVHD suppress CMI

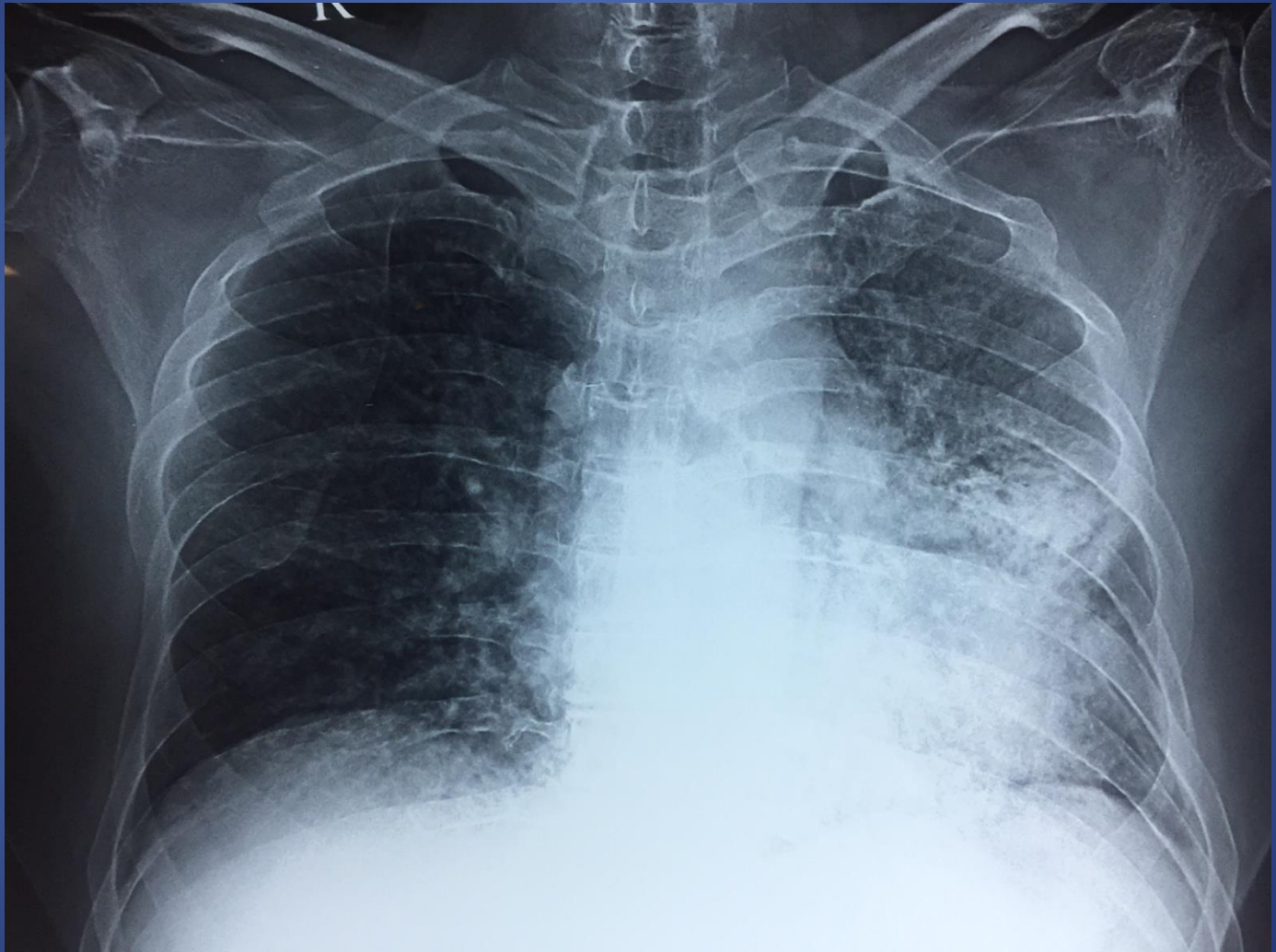


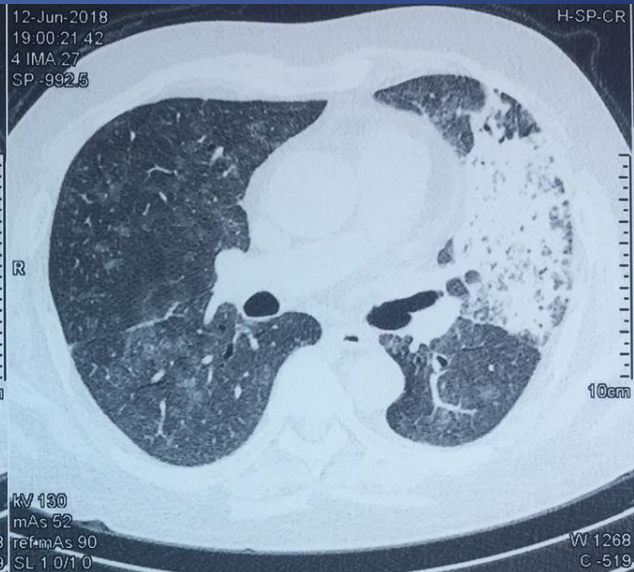
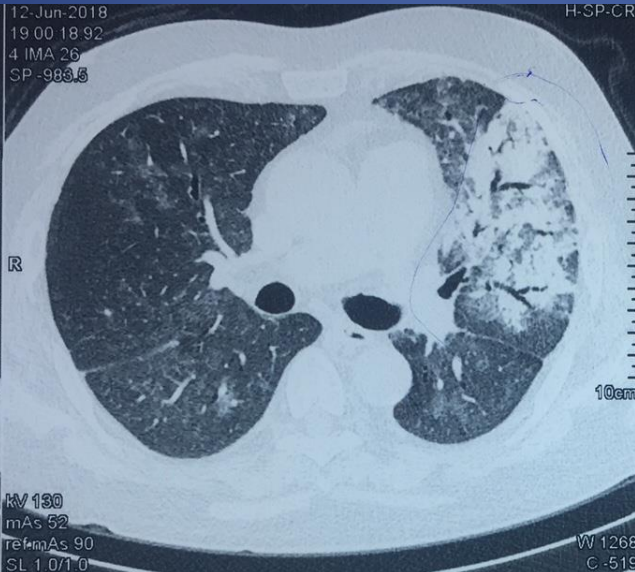
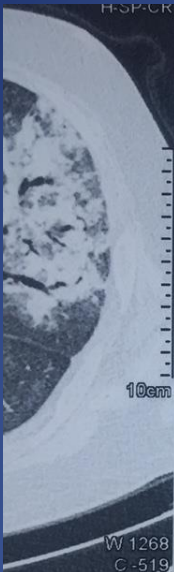
Timeline of infections following HSCT



Case

- 51 male
- From Pondicherry
- Background
 - Primary CNS lymphoma (DLBCL) diagnosed in JAN 2018
- Treatment received
 - Rituximab, Methotrexate, temozolamide
 - Progressive disease
 - Palliative radiotherapy
 - Dexamethasone 8mg/day
- Presented with
 - Fever x 2 weeks
 - Progressive breathlessness
 - URI symptoms + at the beginning
 - No sick contact
 - Attended a temple function one week before the illness





HOSPITALS PV...
DR. BALAMURUGAN

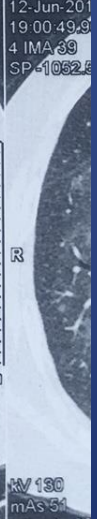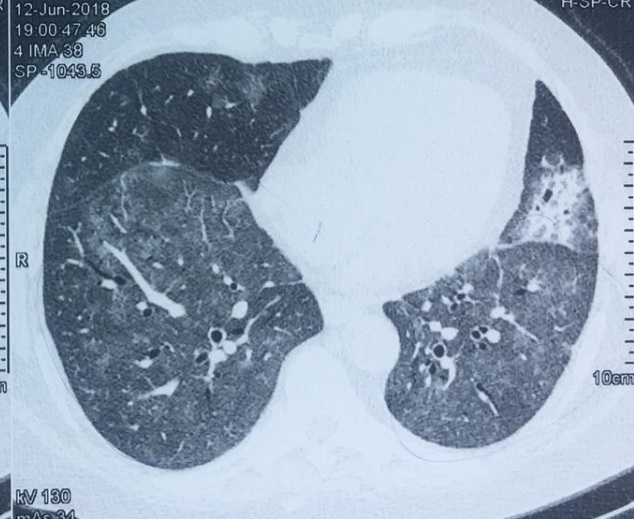
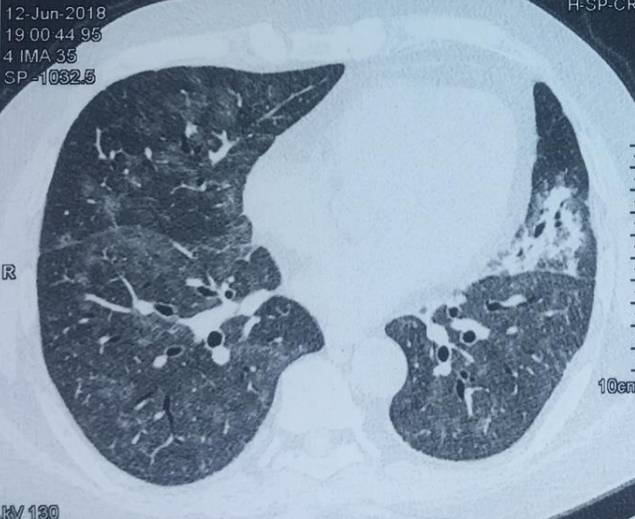
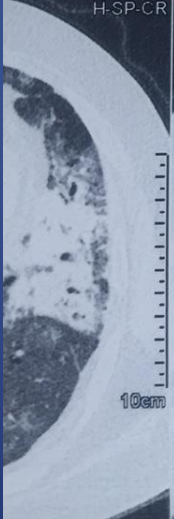
RAMASAMY.MR 52YRS/M
11000

A BRAIN & SPINE HOSPITALS PV...
Ref: DR. BALAMURUGAN

RAMASAMY.MR 52YRS/M
11000

A BRAIN & SPINE HOSPITALS PV...
Ref: DR. BALAMURUGAN

RAMASAMY.MR 52YRS/M
11000



HOSPITALS PV...
DR. BALAMURUGAN

RAMASAMY.MR 52YRS/M
11000

A BRAIN & SPINE HOSPITALS PV...
Ref: DR. BALAMURUGAN

RAMASAMY.MR 52YRS/M
11000

A BRAIN & SPINE HOSPITALS PV...
Ref: DR. BALAMURUGAN

RAMASAMY.MR 52YRS/M
11000

Cont..

- Treated elsewhere
 - As pneumonia
 - Meropenem, Teicoplanin for 7 days
 - CT chest : left upper lobe airspace consolidation and bilateral GGO
- Present condition
 - Hypoxic
 - Intubated, hemodynamically stable, GCS stable
 - No significant examination findings

- TC – 9400
- PLT – 234
- A/G – 2.6/2.8
- Creat -0.6

- He was on
 - Meropenem
 - Targocid
 - Tigecycline
 - Solumedrol

- S.PCT – 0.95
- Mini BAL – c/s negative
- Xpert MTB – negative
- S.BDG - >523
- CMV viral load in mini BAL – 37,906,800 copies/ml
- CMV viral load in plasma – 79230 copies/ml
- RVP – Rhinovirus and Enterovirus detected
- Mini BAL galactomannan – 1.9

Risk factors in our patient

- Primary disease : lymphoma
- Drugs :
 - Rituximab
 - Temozolamide
 - Dexamethasone

Diagnosis is....

- 1. PCP
- 2. Rhinovirus pneumonia
- 3. Aspergillosis
- 4. CMV
- 5. Rituximab lung injury

Diagnosis

- ? Rhinovirus / Enterovirus Pneumonia
- Probable PCP
- Probable CMV pneumonia
- ? Bacterial super-infection
- ? Aspergillus pneumonia
- ?? Rituximab induced lung injury

Case

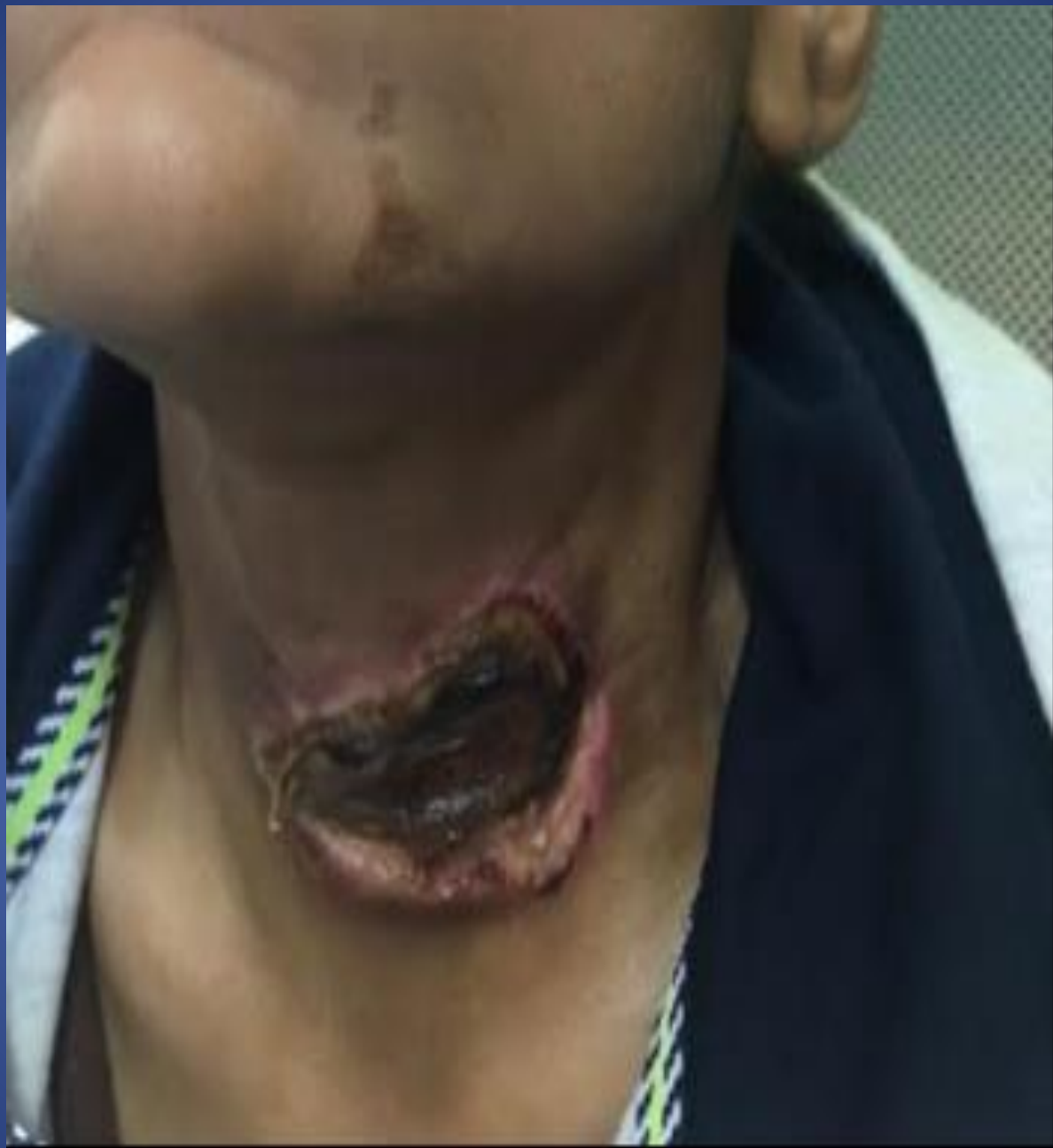- 8 year old boy
- From rural area in Assam
- Recurrent skin lesions since 6 months of birth
- But more since last few months
- Lesions will appear on trunk, neck area, start with small raised spot and then enlarge; may or may not have pus, heal with scar within 2 weeks

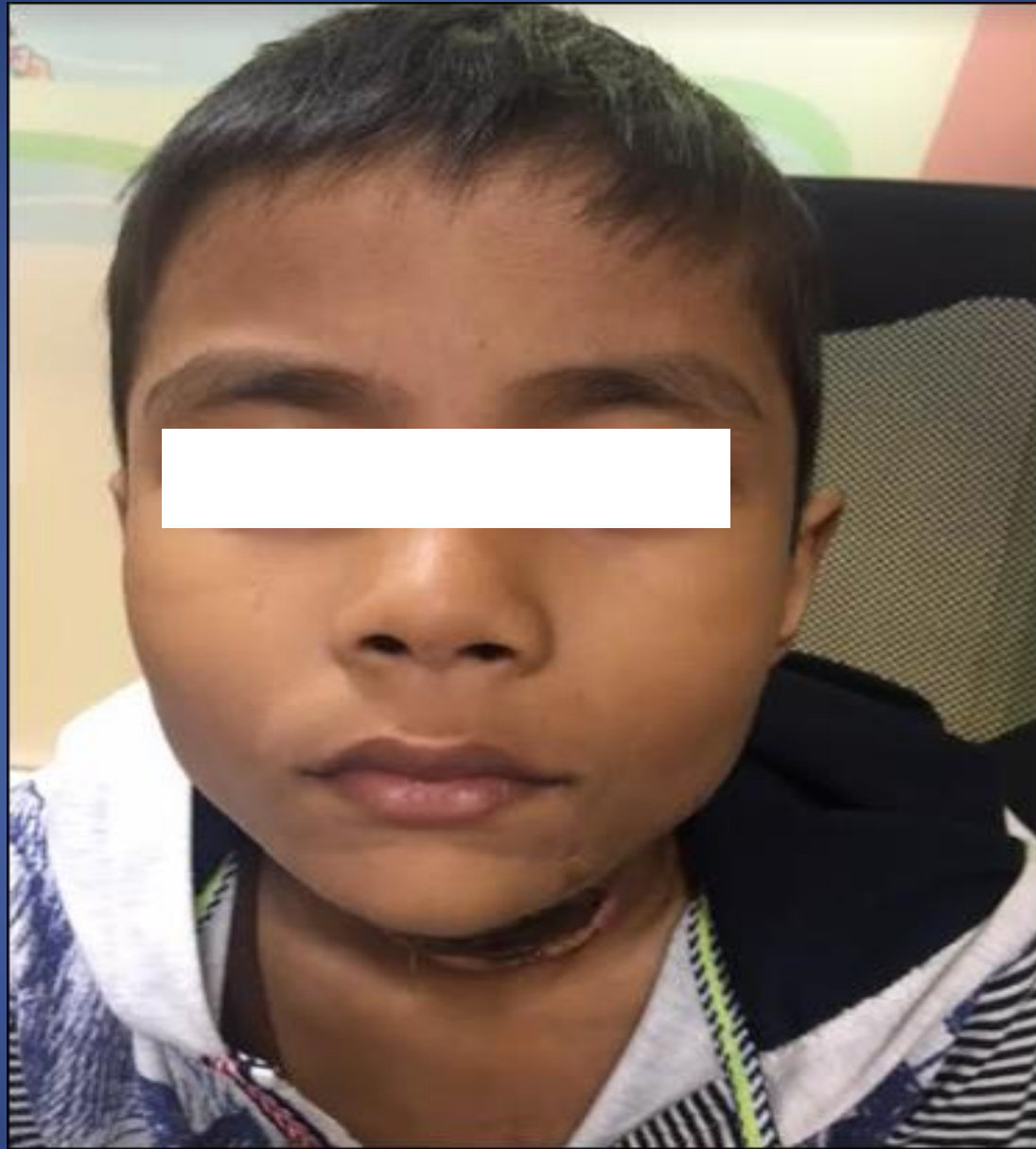- Not gaining height and weight
- Occasional loose stools (once in every 2-3 months)

- No history of pneumonia, recurrent cough, blood transfusion, no vaccination issues, no hospitalisation
- Mother doesn't recall regarding umbilical cord separation
- No history of TB/TB contact
- Still has many temporary tooth

- Born of non-consanguineous marriage
- Has one sibling (elder sister- healthy)
- Parents are apparently healthy

- On examination:
- Low weight and height for his age;
- Scars + over trunk, scalp and neck





Investigations

- Hb: 8.2, TLC: 10,200 (N59/L27/M12), Platelets: 4.4lac
- ESR: 65
- LFT WNL, Chest Xray normal, USG normal
- HIV ELISA: Negative
- Culture: Staph aureus

Diagnosis of underlying disease...

- 1. HIV
- 2. CGD
- 3. CVID
- 4. Job's syndrome
- 5. Idiopathic CD4 lymphocytopenia

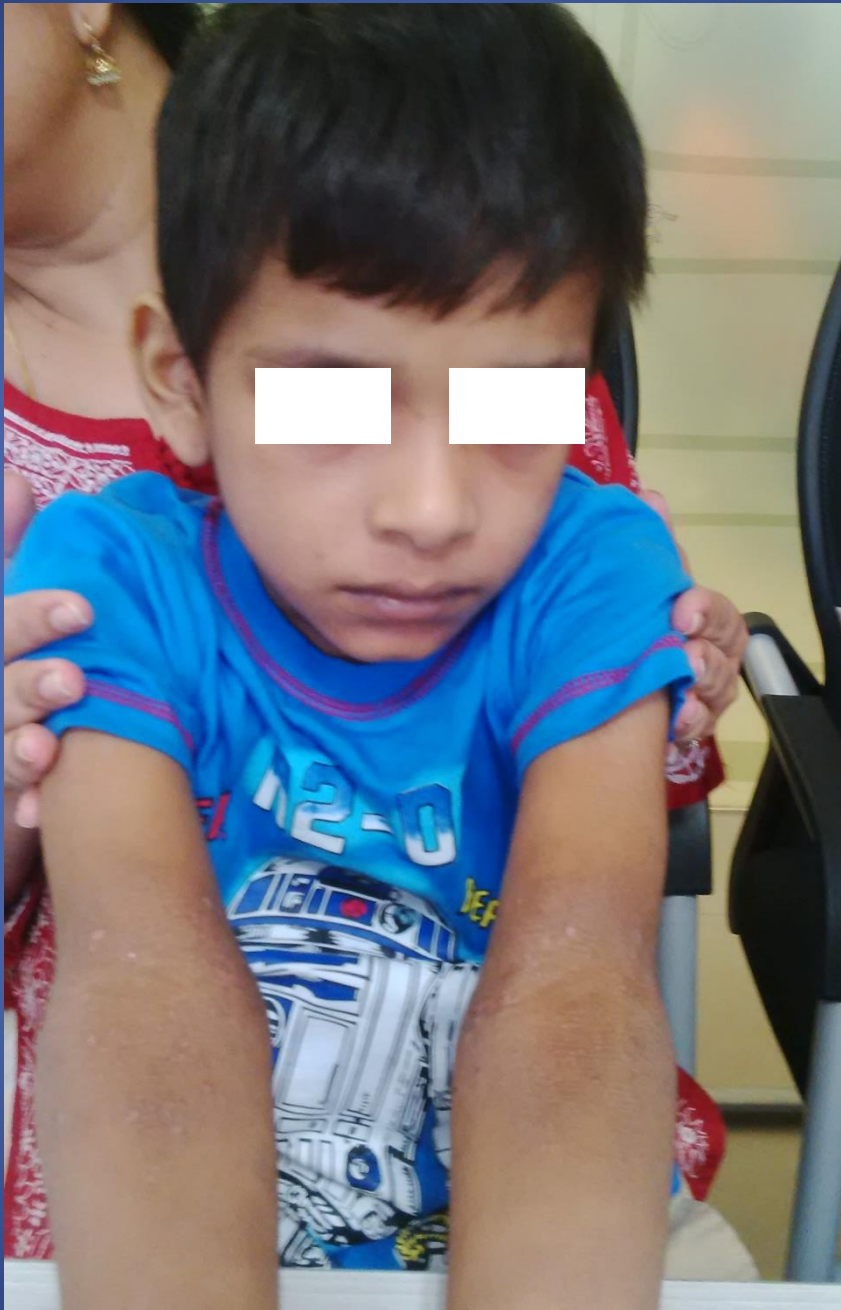- Immunoglobulin profile: normal
 - IgE levels: 1340 IU/mL
 - NBT test: 3%; positive
 - T and B cell markers normal
-
- Chronic granulomatous disease of childhood

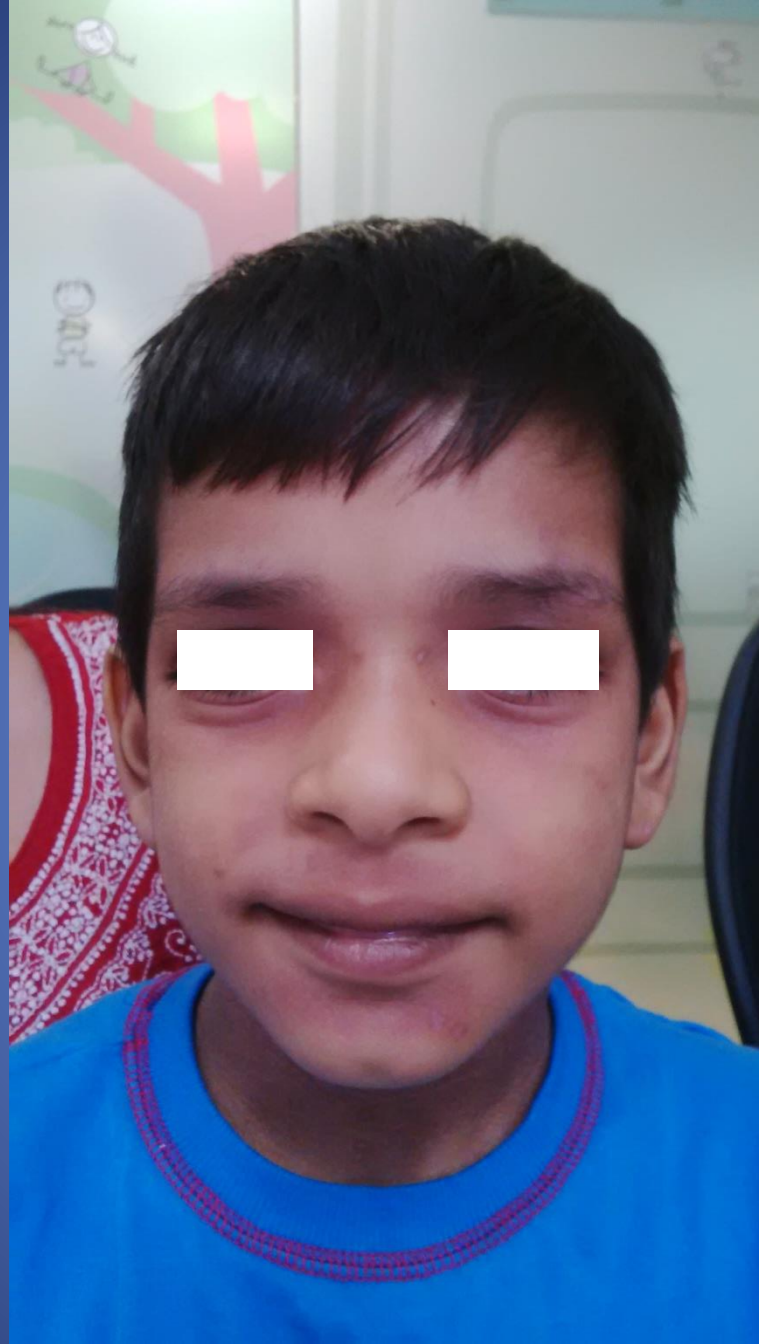Case Vignette

- 6 year old boy from Chennai
- Diagnosed as Atopic Dermatitis 3 years back
- Came to us with following history

- Pustular rash over neck, flexural area 15 days ago along with low grade fever
- Was given amoxyclav for 7 days along with fucidin ointment
- Became better

- 1 week later, developed pain in the right groin, so severe was not able to walk
- Was examined by physician, tender inguinal lymphadenopathy
- Started on cephalexin
- Slightly better
- Nasal swab: MRSA





Diagnosis of underlying disease...

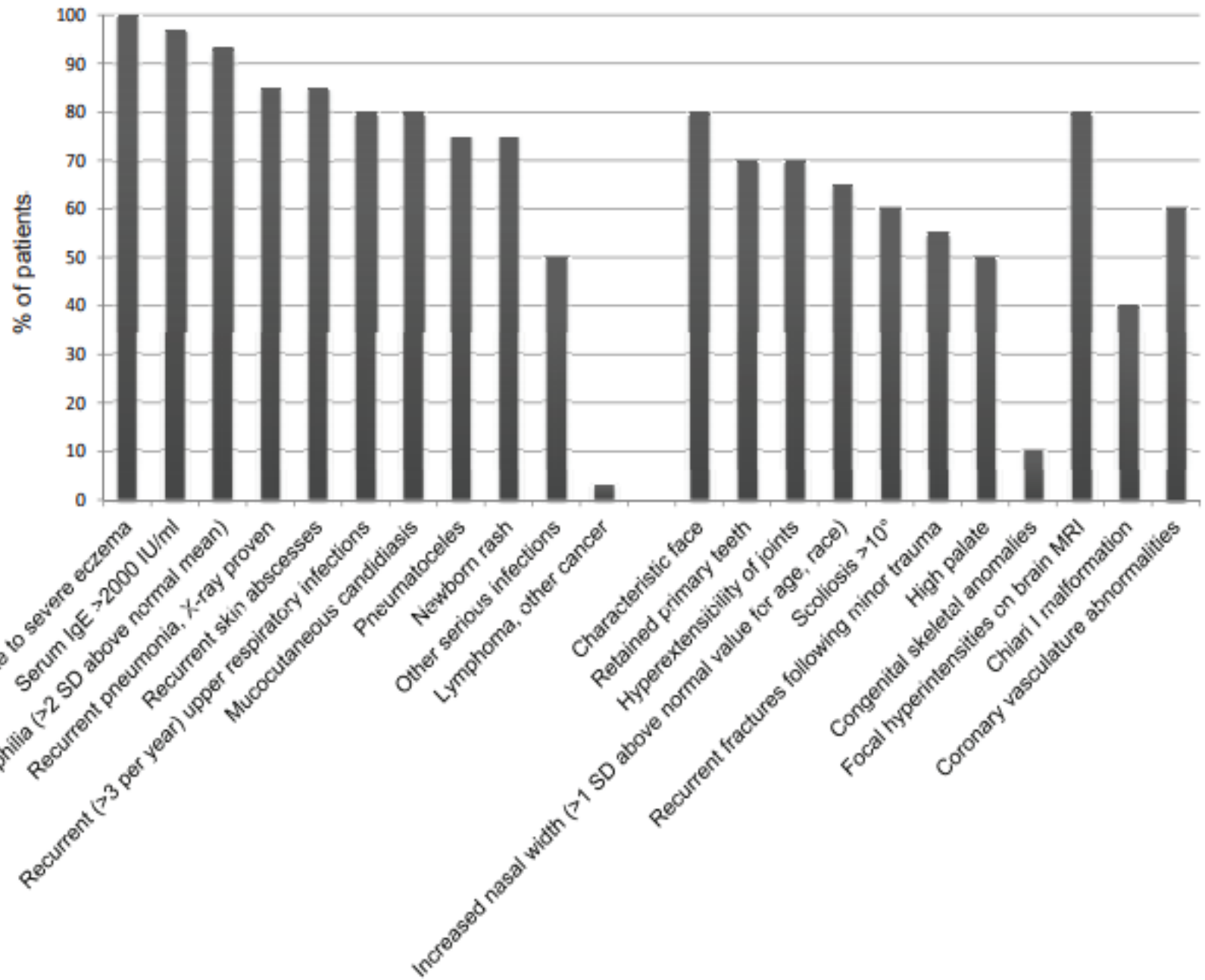
- 1. HIV
- 2. CGD
- 3. CVID
- 4. Job's syndrome
- 5. Idiopathic CD4 lymphocytopenia

Job's syndrome

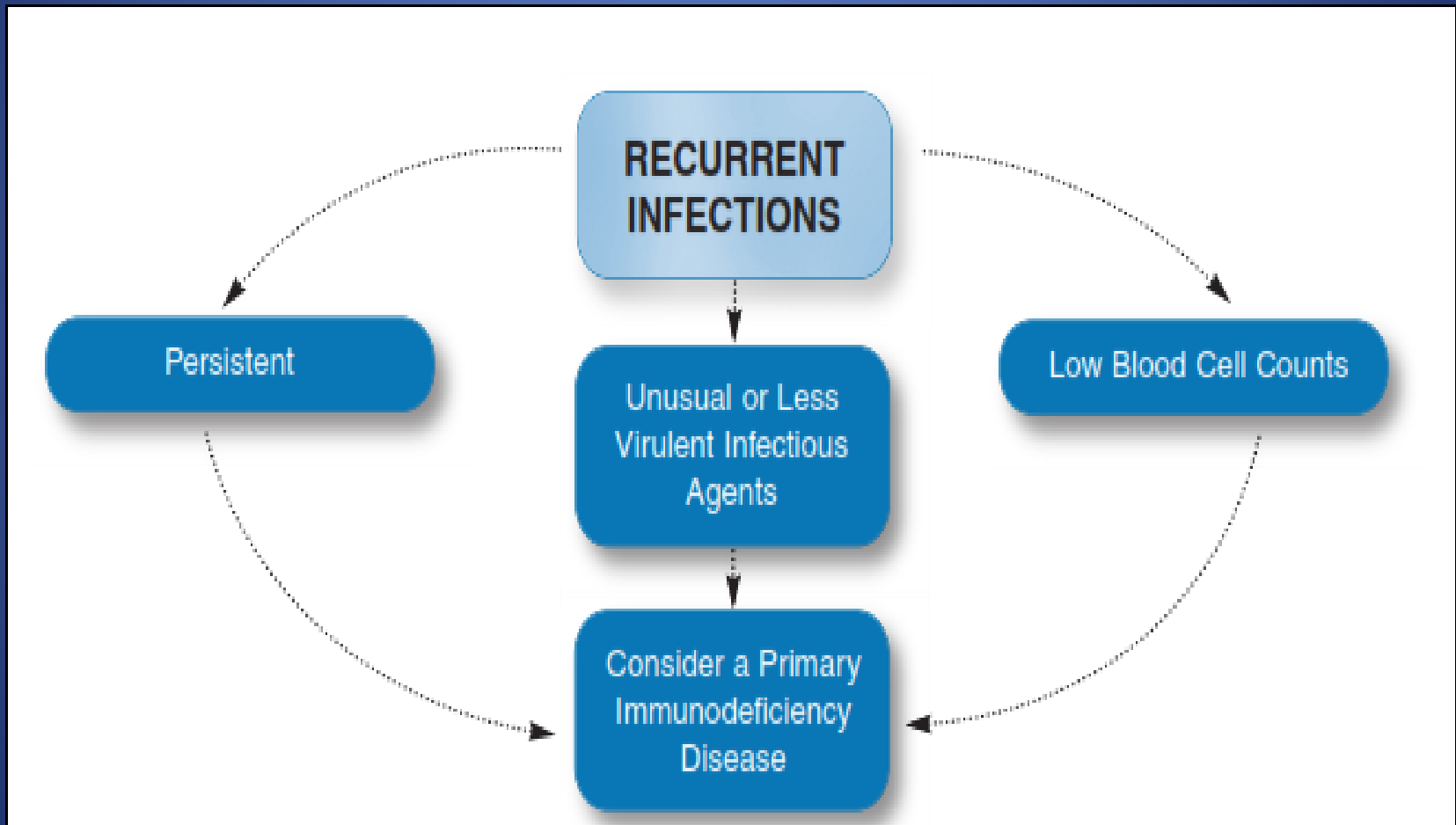
- Serum IgE was 20,000

Immunological and infectious complications

Non-immunological complications



When to Suspect primary immunodeficiency?



Warning Signs

- Four or more new ear infections within 1 year.
- Two or more serious sinus infections within 1 year.
- Two or more months on antibiotics with little effect.
- Two or more pneumonias within 1 year.
- Failure of an infant to gain weight or grow normally.
- Recurrent, deep skin or organ abscesses.
- Persistent thrush in mouth or fungal infection on skin.
- Need for intravenous antibiotics to clear infections.
- Two or more deep-seated infections including septicemia.
- A family history of PID.

Subbarayan A, Colarusso G, Hughes SM, Gennery AR, Slatter M, Cant AJ, *et al.* *Clinical features that identify children with primary immunodeficiency diseases.* Pediatrics. 2011;127:810-6

Case

- 5/F from Guwahati
- Fever and cough for last 4 months
- Breathlessness for last 1 week
- Started with cough and cold which was treated with azythromycin for 5 days
- Fever is high grade, intermittent, no chills, no diurnal variation

- Cough (wet), with no hemoptysis, no chest pain
- Loss of wt (2 kgs)
- Loss of appetite

- Normal in the past
- Mother have suffered from stroke
- And had 2 first trimester abortions
- Elder sibling has expired because of pneumonia at age of 18 months

On examination

- Dyspneic
- Requiring 4l/min of O₂
- PR: 140/min
- Clubbing
- Pallor+
- Chest crepts+

- Abdomen distended in upper part
- Liver palpable 5cms below coastal margin, firm
- No other organomegaly

Review of Old Records

- Was admitted in April 2018 for similar complaints, found to have pneumonia and UTI (no urinary complaints) – due to E coli
- Was treated with amikacin for 10 days
- Hb: 9.8
- TLC: 25000 (P90)
- Normal platelets

ACH

- Hb: 9
- TLC: 32000 (P90)
- Plat: 3.5lac
- ESR: 78
- CRP: 75
- AST: 79
- ALT: 85
- Rest LFT normal

Patient ID : ACH1.0000161380

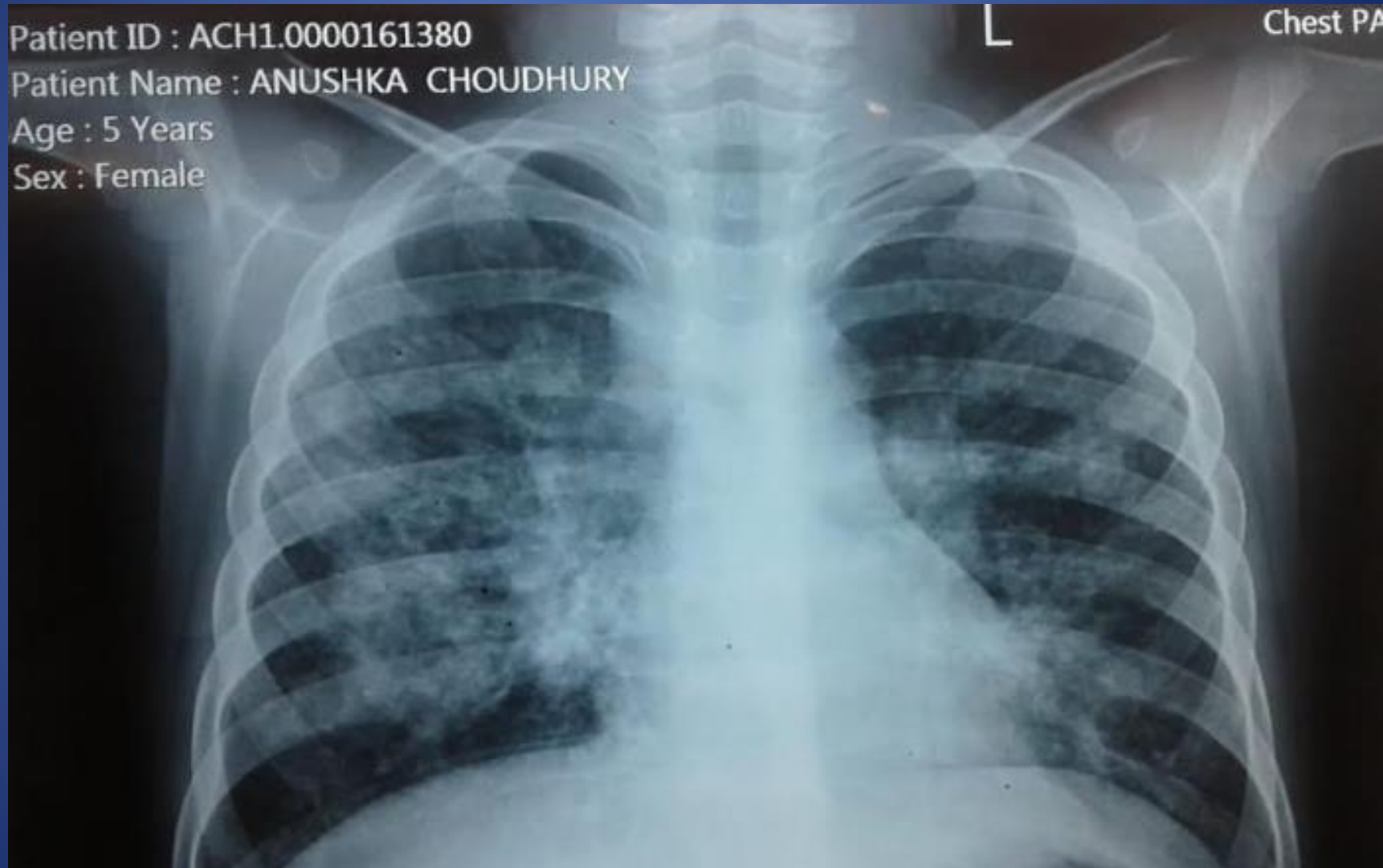Patient Name : ANUSHKA CHOUDHURY

Age : 5 Years

Sex : Female

L

Chest PA

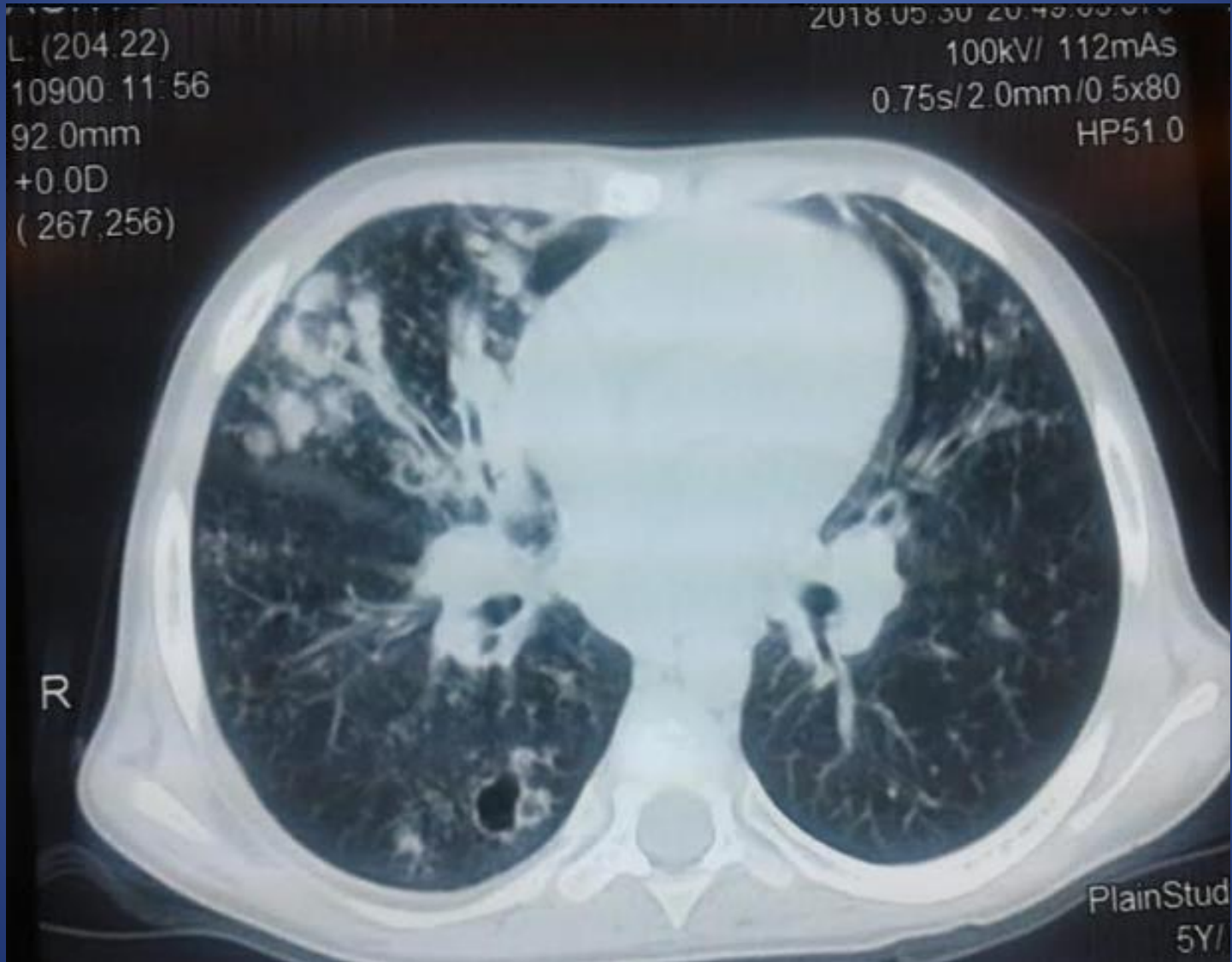

- Have been on Piptaz (Day 3)
- Not improving; still requiring Oxygen and Having fever
- Asked for CT chest and immunodeficiency work up
- Added clindamycin and voriconazole

L (204.22)
10900 11:56
92.0mm
+0.0D
(267,256)

2018.05.30 20:49:00.010
100kV/ 112mAs
0.75s/2.0mm/0.5x80
HP51.0

R



PlainStud
5Y/

BAL

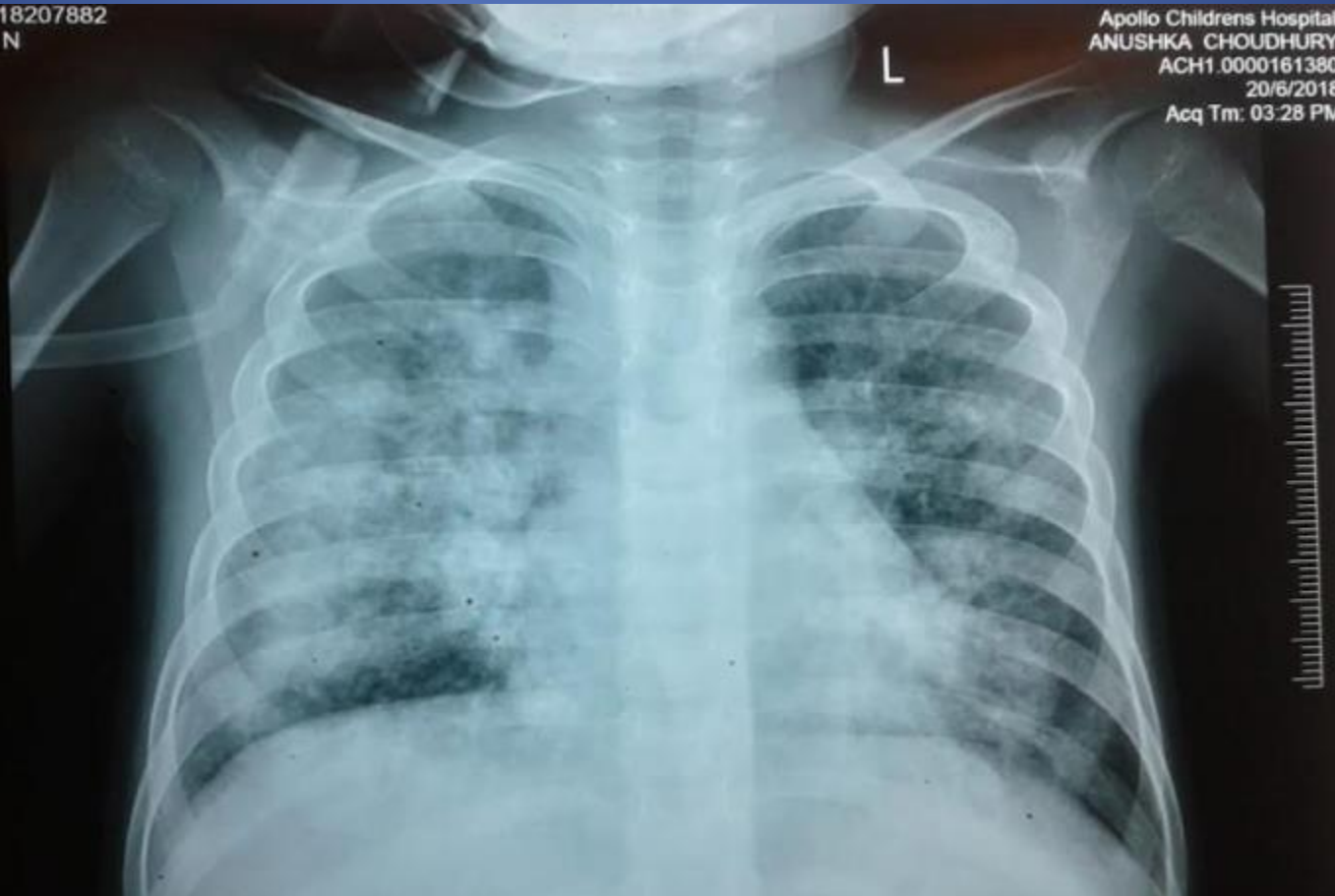
- Xpert MTB: negative
- Staph aureus grown (MSSA)
- Nocardia stain negative
- Aspergillus GM: 0.38
- Fungal and AFB stain negative

- After adding clindamycin and voriconazole, child became afebrile after 48 hrs; oxygen requirement also decreased, was shifted to ward
- As she was afebrile for last 5 days, planned for discharge
- Piptaz and voriconazole stopped and discharged on oral clindamycin

- After 10 days pt came to OP with c/o
- Fever for 5 days, breathlessness and intermittent hemoptysis

10107.118207882
DAGA J N

Apollo Childrens Hospital
ANUSHKA CHOUDHURY
ACH1.0000161380
20/6/2018
Acq Tm: 03:28 PM



- Work up for primary immunodeficiency was negative
- HIV negative
- Sweat chloride test negative

- Readmitted
- Started on Meropenem, Linezolid, Voriconazole
- Blood cultures
- GPC (4/4)
- Meropenem stopped, started on vancomycin and cefazolin
- TTE: normal

- MSSA in blood
- Shifted to Cefazolin
- BDG: 404
- CT abd: fatty infiltration in liver with atrophic pancreas
- Fecal elastase levels: low

Underlying disease is....

- 1. CVID
- 2. Cystic fibrosis
- 3. Job's syndrome
- 4. CGD
- 5. Idiopathic CD4 lymphocytopenia

- Day 5 into 2nd admission
- Persistently febrile, with worsening respiratory distress
- Repeat blood cultures (after 48hrs if initiation of MSSA cover) negative

- New Blood culture: GNB
- GNB--- B cepacia
- Sputum Culture: Pseudomonas

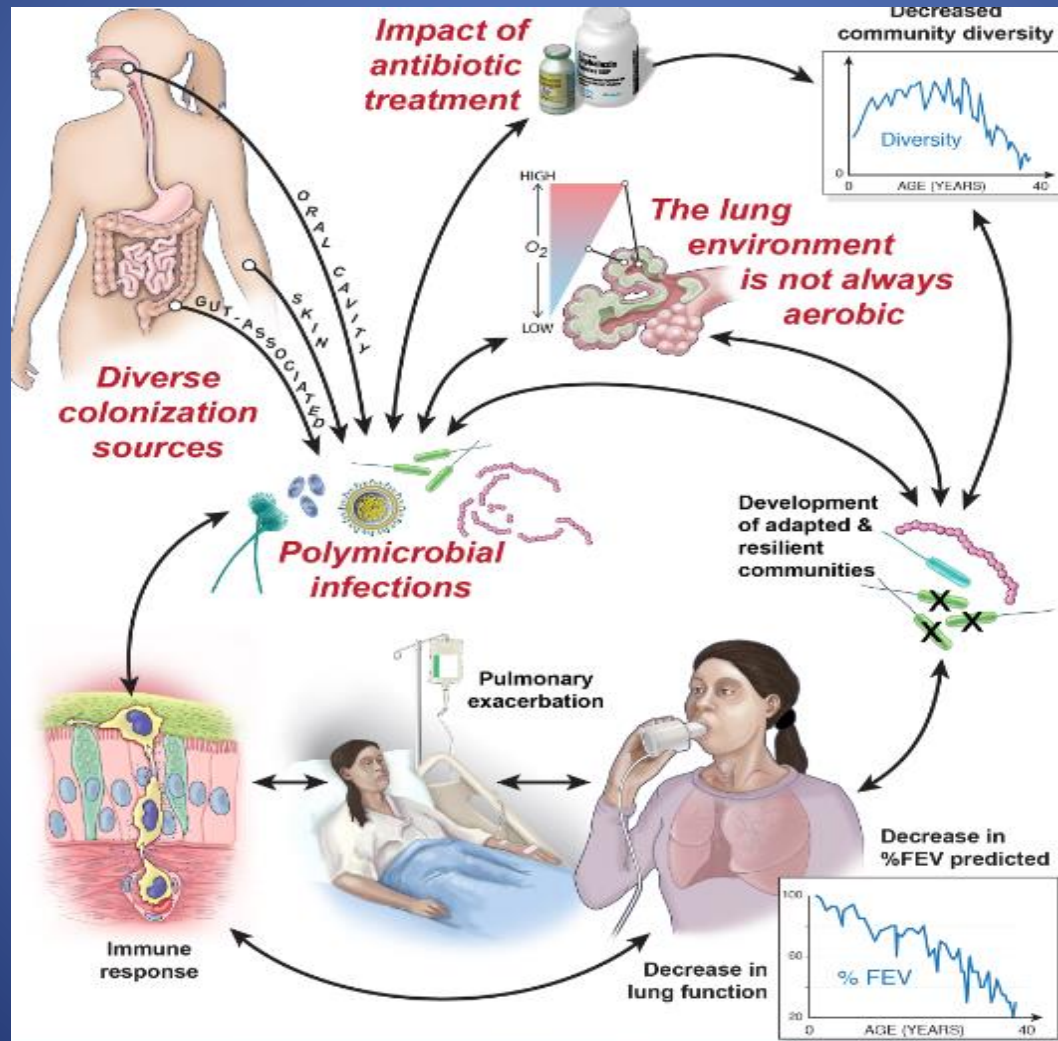
Cystic Fibrosis and Infections

- Cystic fibrosis (CF) manifests as a clinical syndrome characterized by chronic sinopulmonary infection as well as by gastrointestinal, nutritional, and other abnormalities.
- Disease of exocrine gland function

Diagnosis

- Requirements for a CF diagnosis include either positive genetic testing or positive sweat chloride test findings (>60 mEq/L) and 1 of the following:
 - Typical chronic obstructive pulmonary disease
 - Documented exocrine pancreatic insufficiency
 - Positive family history (usually affected sibling)

Lung Infections in CF



PSEUDOMONAS AERUGINOSA

- Most common bacterial pathogen
- Colonizes CF patients in more than 50% of cases
- CF patients chronically infected by *Pa* show a steeper lung function decline (expressed as FEV1 decline over time), a higher number of pulmonary exacerbations, more hospital admissions and higher mortality than *Pa*-free patients.
- Forms **biofilms**

***BURKHOLDERIA CEPACIA* COMPLEX**

- *B. cepacia* complex (Bcc) is a group of at least 17 related species (genomovars)
- Genomovar I (*B. cepacia*), II (*B. multivorans*), III (*B. cenocepacia*), IV (*B. stabilis*), V (*B. vietnamiensis*), VI (*B. dolosa*), VII (*B. ambifaria*), VIII (*B. anthina*), IX (*B. pyrrocinia*)
- Represent a challenge because of its **intrinsic antibiotic resistance**.
- *Burkholderia gladioli* and *Burkholderia pseudomallei*
- Pulmonary exacerbation should be treated with combination antibiotic therapy after **susceptibility test results**.

S. aureus

- This is the **first pathogen** to infect and colonize the airways of CF patients
- Cause epithelial damage, opening the way to the **adherence of other pathogens** such as *Pseudomonas aeruginosa*
- Not entirely clear - the proportion of CF patients with *S. aureus* in their lower airway causing frank disease.
- While sputum clearance of *S. aureus* was achieved in most studies, none documented a positive effect on pulmonary function or other clinical outcome
- Definitive evidence of treating *S. aureus* from sputum samples is lacking

In summary

- Take a careful history
- Classify the immune defect
- Know the timeline of infection
- Be aggressive in workup
- Molecular/rapid diagnostics essential: if not available in hospital , send out!
- May need empiric therapy pending diagnostics
- More than one infection may be present
- Watch for drug interactions between anti-microbials and other medications
- Once infection confirmed, minimize the immunosuppression where possible



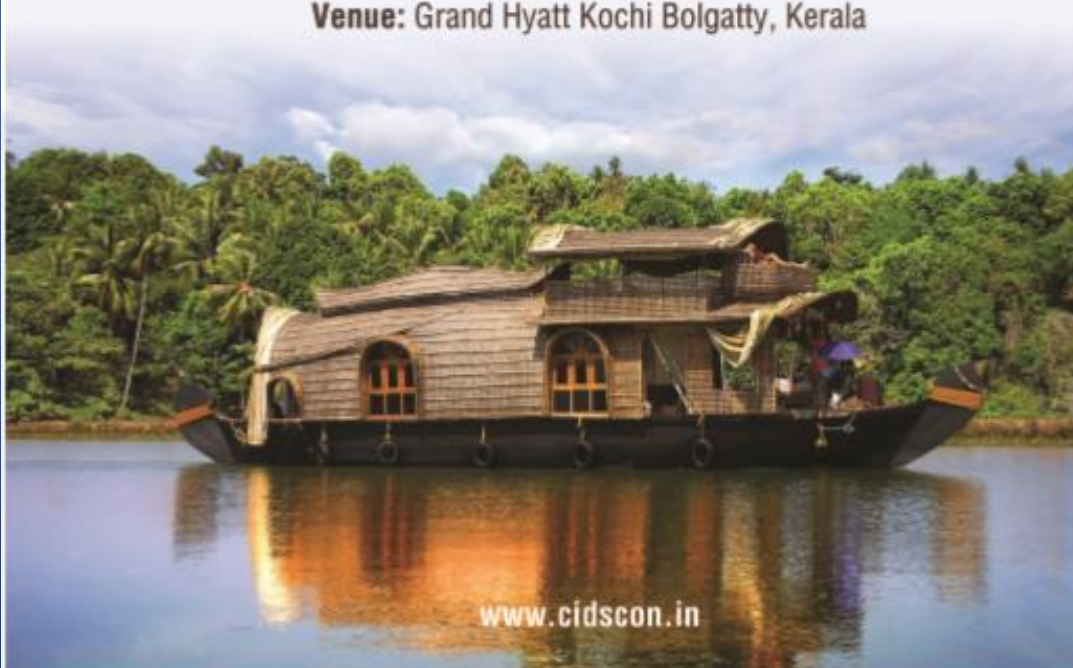
CIDSCON 2019

9th Annual Conference of
Clinical Infectious Diseases Society

23rd | 24th | 25th August 2019, Kochi

Theme: Simplifying the evidence- the next step for progress in Infectious Diseases

Venue: Grand Hyatt Kochi Bolgatty, Kerala



www.cidskon.in

Are you an MD/DNB (Internal Med) interested in an ID career?

▶ DM (Infectious Diseases)

- ▶ Three year program
- ▶ CMC, Vellore and AIIMS, New Delhi

▶ FNB (National Board of Examinations):

- Two year fellowship
- Apollo Hospitals Chennai & Hinduja Hospital, Mumbai
- Apollo Hyderabad & Sterling Hospital Ahmedabad added
- For details go to NBE website

▶ Tamil Nadu Dr. MGR Medical University:

- Two year fellowship
- Apollo Hospitals Chennai, Global Hospitals Chennai and CMC, Vellore
- Contact institutions for details